

# Handbook for Recognizing, Evaluating, and Documenting Human Interaction in Stranded Cetaceans and Pinnipeds



**Susan Barco**  
Virginia Aquarium Stranding Program

**Kathleen Touhey**  
Cape Cod  
Stranding  
Network, Inc.



## **Acknowledgments**

We would like to extend our gratitude to the many organizations and individuals who have contributed to the development of this protocol. The work presented here was funded by the NOAA John H. Prescott Grant Program (CCSN Award: NA04NMF4390044, VAQSP Award: NA03NMF4390483). The staff and volunteers of the Virginia Aquarium Stranding Team and the Cape Cod Stranding Network provided valuable data for this work. Additional case studies were provided by Dr. Frances Gulland (The Marine Mammal Center, Sausalito), Connie Merigo (New England Aquarium), and Kim Durham (Riverhead Foundation). We would also like to thank Bill McLellan (University of North Carolina, Wilmington, VABLAB), Greg Early, Janet Whaley (NOAA Office of Protected Resources), Brian Moore (NMLC) for editorial efforts and NOAA Fisheries OPR Northeast Region and Headquarters for their guidance and support.

## **Preface**

This project evolved from joint effort and John H. Prescott Marine Mammal Rescue Assistance Grant Program awards to the Cape Cod Stranding Network, Inc. (CCSN) and the Virginia Aquarium Stranding Response Program (VAQS) where the authors proposed to develop a human interaction training program for the Northeast Region Stranding Network in the US. At the time of the awards, there was no finalized national human interaction data sheet and the project transformed to include development of a data sheet, data sheet instructions, and a training program. Upon completion of the regional work, the authors proposed to the national stranding coordinator, Dr. Janet Whaley, to provide the training to all stranding networks in the U.S.

The information detailed in this handbook is designed to accompany the training program and to serve as a desk reference for stranding responders.

## Table of Contents

### Background

Goals and objectives of this protocol .....	4
Why evaluate stranded marine mammals for signs of human interaction? .....	4
Putting the data to use .....	4

### The Basics

Definitions .....	5
The importance of being conservative .....	6
Strategy for evaluation .....	6

### Guidelines for Documenting Human Interaction

Introduction to the protocol .....	7
Final decisions .....	8
Using the data sheet .....	9
How to describe what you see .....	9
Images and video .....	9
Collecting physical evidence .....	9
Tips for conducting an evaluation .....	10

### Recognizing Human Interaction

Types of wounds and lesions observed .....	10
<b>Vessel Interactions</b> .....	11
Definitions .....	11
Evidence and marks commonly observed (w/examples) .....	11
Case study #1 .....	20
<b>Debris Entanglement</b> .....	27
Definitions .....	27
Evidence and marks commonly observed (w/examples) .....	27
<b>Debris/gear ingestion</b> .....	28
Definitions .....	28
Evidence and marks commonly observed (w/examples) .....	28
Evaluating Debris/Gear Interaction Cases .....	29
<b>Vessel Interactions</b> .....	30
Definitions .....	30
Sharp trauma (propeller strike) .....	30
Evidence and marks commonly observed (w/examples) .....	31
Evaluating Sharp Vessel Trauma Cases .....	33

<i>Evaluating a Decomposed Sharp Vessel Trauma Case .....</i>	34
<i>Blunt trauma .....</i>	35
<i>Evidence and marks commonly observed (w/examples) .....</i>	36
<i>Case study #2 .....</i>	38
<b>Other Types of Human Interaction .....</b>	40
<i>Gunshot and other penetrating wounds .....</i>	40
<i>Evidence and marks commonly observed (w/examples) .....</i>	40
<i>Harvest/mutilation .....</i>	42
<i>Definitions.....</i>	42
<i>Evidence and marks commonly observed (w/examples) .....</i>	43
<i>Evaluating a Harvest/Mutilation Case .....</i>	43
<i>Harassment/human interference .....</i>	44
<i>Definitions.....</i>	44
<i>Evidence and marks commonly observed (w/examples) .....</i>	44
<i>Unknown or undetermined interactions .....</i>	45
<i>Evaluating an Undetermined Interaction Case .....</i>	45
 <b>Confounding Variables</b>	
<i>Natural and unknown marks .....</i>	46
<i>Immediate death .....</i>	50
<i>Predation/scavenger damage.....</i>	50
<i>Decomposition.....</i>	54
<i>Evaluating a Decomposed Carcass .....</i>	56
 <b>Necropsy and Sampling</b>	
<i>The importance of an internal exam .....</i>	57
<i>Standardized protocol .....</i>	57
<i>Necropsy report.....</i>	57
<i>Suggested sampling .....</i>	58
 <b>Outreach and Education</b>	
<i>The role of public sentiment in conservation and management .....</i>	58
<i>Being sensitive to other resource users .....</i>	58
 <b>Appendices</b>	
<i>Appendix I: Data sheet .....</i>	60
<i>Appendix II: Instructions .....</i>	62

## **Background**

### ***Goals and objectives of this protocol***

The goal of this protocol and the accompanying training material is to provide stranding network personnel with the tools needed to evaluate marine mammals for signs of human interaction (HI) and to collect HI data consistently in all regions of the United States. This goal will be achieved by accomplishing the following objectives:

- Define the terms associated with human interaction evaluations
- Explain the importance of being conservative
- Provide an understanding of how HI data may/should be used
- Introduce a standardized examination protocol and accompanying data sheet
- Provide guidelines for recognizing and documenting evidence of human interaction found on stranded marine mammals

The protocol presented within this document will yield two important pieces of information. The first is an *objective evaluation* of an animal or carcass that determines whether any signs of human interaction are present on the animal (regardless of whether they are pre- or post-mortem, healed or recent). The second is a *subjective finding* in which the examiner uses all available information to evaluate the likelihood that any observed evidence of HI contributed to the stranding event.

### ***Why evaluate stranded marine mammals for signs of human interaction?***

When human interaction data are gathered objectively and consistently they can provide a solid scientific foundation for conservation and management measures. Documenting the types of interactions that take place and identifying the spatial and temporal patterns associated with the interactions can highlight resource use conflicts. With a better understanding of the interactions, appropriate measures can be taken to resolve conflicts.

Furthermore, in the United States, the collection of human interaction data is mandated under the Marine Mammal Protection Act. The National Oceanic and Atmospheric Administration (NOAA) Fisheries Service requires that HI data be submitted with other basic information (such as species, stranding date and location, length, etc.) on each stranded animal.

### ***Putting the data to use***

Human interaction data are frequently and easily misinterpreted. In the United States, Level A Data, including human interaction findings, are collected from each stranded marine mammal. The Level A data sheet asks "Findings of human interaction?" with multiple choice answers of YES, NO, or CBD (could not be determined). However, different organizations and individuals often interpret this question differently. The federal instructions for the data sheet state that the question is designed to determine whether or not there are signs of interaction present on the animal. This does not necessarily mean the interaction caused the stranding or the death of the animal.

**Are there signs of  
HI on the animal?**

Consistently following the protocol  
allows you to answer this  
question.



By standardizing the way we examine the animals, collect data, and document interactions, we ensure that we are not only answering the same question, but using the same basis to draw our conclusions. This protocol defines the terms we use to describe and categorize interactions. All organizations implementing this protocol and utilizing the data sheet will collect comparable data, affording the opportunity to analyze data on a broader scale. The final subjective conclusion on the data sheet requires the examiner to combine the objective conclusion from the data sheet with the event history and sample analyses. This allows the examiner the opportunity to evaluate the likelihood that an observed interaction contributed to the stranding of the animal.

Evaluating the data sheet and event history allows you to answer this question.



**Did HI contribute to the stranding event?**

However, the protocol is NOT designed to determine whether an observed interaction caused the death of an animal. Making this conclusion requires a full necropsy and sampling, and the diagnoses of veterinarians and pathologists.

When collected carefully and consistently, these data can be used to describe the types of

**Did HI cause the death of the animal?**

To answer this question, requires all sample results and vet/path review.



interaction taking place (e.g. monofilament vs. multifilament net entanglement, small or large vessel interaction, ingestion of debris, harassment, etc.). These data can provide a sound scientific basis for policy and management decisions, but the nature of strandings makes it inadvisable to use human interaction data to estimate mortality or changes in mortality rate due to human interaction.

## **The Basics**

### ***Definitions***

There are several key terms used in this protocol. It is important to define the terms the same way in order to ensure that our data are comparable.

- **YES** - you have examined the area/animal and you found clear signs of human interaction
- **NO** - you have examined the area/animal and you did NOT find signs of human interaction
- **CBD** (could not be determined) - you are unsure whether there are any signs of human interaction
- **NE** (not examined) - you did not examine the area
- **NA** (not applicable) - this question is not applicable

### ***The importance of being conservative***

In addition to standardizing our protocols and maintaining objectivity when examining animals, it is essential to be conservative in our evaluations. Since these data may be used to generate policies and management strategies, they must stand up to scientific scrutiny. By making very conservative evaluations, we can ensure our data are robust and strong.

Again, for the sake of consistency, we must establish what it means to be conservative. The most conservative diagnosis is always CBD (Could not Be Determined). This is a fundamental premise of this protocol. It is best understood by thinking of it this way: every animal or carcass is a CBD until proven otherwise. If evidence of human interaction is found, then the objective finding is YES, there were signs of HI. If the animal is thoroughly examined and no evidence of HI is found, then the answer is NO. However, if any factors compromise your ability to evaluate the carcass properly or thoroughly, then the finding must remain CBD. The factors that can affect your ability to evaluate a stranded animal for signs of HI include, but are not limited to: decomposition, scavenger damage, predation, inexperience in conducting these exams, logistics (large animals that one cannot manipulate to examine both sides), *etc.* (See *Recognizing Human Interaction: Confounding Variables*).

The reality is that it is much easier to say YES than it is to say NO. Take the following scenarios as an example:

Scenario 1: a decomposed seal carcass washes ashore. Some fur is missing from the right front flipper and both rear flippers and the exposed skin is red and sun burned. There is a circumferential wound (laceration) around its neck deep into the muscle layer. The edges of the laceration appear clean and smooth. Although, the source of the wound is not readily apparent (*e.g.*: there is no gear on the animal), the wound is consistent with a ligature mark. One can definitively score this as a YES for signs of HI.

Scenario 2: a decomposed seal carcass washes ashore. Some fur is missing from the right front flipper and both rear flippers and the exposed skin is red and sun burned. (This is the same animal as in Scenario 1, without the ligature mark.) One cannot definitively score this animal as a NO because several of the areas could not be evaluated due to the physical degradation. Thus the only reasonable finding is CBD.

So, it is easier to have a YES finding in this case, but impossible to have a NO finding. It only takes one piece of evidence of HI to have a finding of YES for even a decomposed carcass, but it takes a full, uninhibited examination of all parts of the animal (and a necropsy of dead animals) to generate a conclusion that there was no evidence of HI. When you cannot definitively say YES or NO, you must conclude that the presence or absence of HI could not be determined (CBD). Thus, CBD is the most conservative answer.

CBD can mean any of the following:

- The carcass was too decomposed, scavenged or preyed upon to examine thoroughly
- The animal was logistically impossible to examine
- The examiner was unsure of the origin of marks on the animal
- There were other factors that confused evaluation

### ***Strategy for evaluation***

Since CBD is a conservative diagnosis, assume the answer is CBD and try to prove otherwise. If you have conducted a thorough examination and find no signs of HI, the diagnosis is **NO**. If you have conducted a thorough examination and find clear signs of HI, the diagnosis is **YES**. If all examiners begin with this premise, it will ensure the evaluations are consistently conservative.



The data sheet will drive your examination by leading you through the protocol. To begin, observe the whole animal. Be systematic in your examination, conducting it the same way each time. Provide an overall external description of what you see. Next, examine each anatomical area thoroughly, recording your observations. If the animal has died or has been euthanized, conduct a thorough necropsy. Sample all evidence of HI, as well standard samples for histopathology, toxicology, genetics, *etc.* Be sure to document your observations (both external and internal) through images and detailed notes. Once you have completed your gross examination, review your observations to determine whether signs of human interaction are present on the animal (*objective evaluation*). Now, review the stranding history and all other available information to make a final HI evaluation (*subjective evaluation*), providing detailed information justifying your findings.

Numbers that refer to instructions and can be used to reference a field in the Comments section

Information about the external condition of the animal

Definitions

Whole body exam

Detailed exam of anatomical areas and information about type and origin of HI lesions



Field #: \_\_\_\_\_

INTERNAL EXAM		YES	NO	Partial	CBD	Image taken	Detailed Info (circle all that apply)	
31	Internal exam conducted						Details in Comments section -use line number	
32	Bruising/blunt trauma						Details in Comments section -use line number	
33	Skeleton examined						Details in Comments section -use line number	
34	Broken bones present						Associated tissue reaction: YES NO CBD	
35	GI tract examined (circle contents)						intact prey partially digested hard parts only debris/gear empty other	
36	Lungs/bronchi examined						Details in Comments section -use line number	
37	Lungs/bronchi contents						froth fluid air ( color: )	
38	Other pathologies noted						Details in Comments section -use line number	
39 Comments (note line number from left margin before each comment):								
40 Signs of Human Interaction Observed: YES NO CBD (transfer to Level A Datasheet)								
41 Stranding Event History/Circumstances:								
42 FINAL HUMAN INTERACTION EVALUATION: If you circled YES above (#40), evaluate the external exam, necropsy, carcass condition and circumstances surrounding the stranding event to answer the question below. How likely is it that the documented human interaction contributed to the stranding? 0: Uncertain (CBD) 1: Improbable 2: Suspect 3: Probable								
43 Justification:								

Data Sheet developed by CCSN & YAGS (12/27/2005) with funding from the John H. Prescott Grant Program

**Internal Exam** →

**Comments section** →

**Objective observation, to be placed on Level A data sheet** →

**Circumstances surrounding the stranding event** →

**Subjective final diagnosis-this is essentially a confidence level** →

**Justification for final evaluation, takes into account event history, experience of evaluator, etc.** →

### Using the data sheet

The data sheet is designed to lead the examiner through the protocol step by step. Begin by reading and becoming familiar with the instructions that accompany the data sheet. Then, following the sheet each time an evaluation is done will help the examiner establish a routine in conducting the examination. Some basic guidelines will help develop consistent, systematic data collection:

- Be sure to fill in all spaces; do not leave any items blank
- Be objective in your examination
- Have the recorder repeat data back to the observer as it is written
- Provide as much detail as possible; use the comments section
- Event history is important – note any report details, witness accounts, fishing and other activities in the area, etc.

For comprehensive and detailed instructions for completing the Human Interaction Evaluation data sheet, please see Appendix B: Instructions.

### Final Decisions

After completing the evaluation, the examiner must complete two final sections.

- 1) *Signs of human interaction observed* – based on your objective observations, were there any signs of HI on the animal? (YES, NO, CBD). This answer will be transferred to the NOAA Fisheries Level A data sheet.
- 2) *Final human interaction evaluation and justification* – a subjective interpretation of

your results. Using all of the information available, indicate the likelihood that the observed human interaction contributed to the stranding event? This is represented on a scale of 0-3 (0=Uncertain or CBD, 1=Improbable, 2= Suspect, 3=Probable). This scale functions as a confidence level. This subjective finding should take into account the experience level of the examiner, physical findings, stranding history and circumstances, results of laboratory analyses, and the findings of veterinarians, pathologists and other experts.

### ***How to describe what you see***

When describing the marks you see on an animal (natural or anthropogenic), be as detailed as possible. Note the location on the body relative to landmarks, the size (length, width, and depth), shape, color, texture, smell, *etc.* If there appears to be a series of wounds or lesions, note the distance between them, from the center of each lesion. Examiners often feel the need to use highly technical terms to describe what they are seeing. This is not necessary; instead, use terms you are most comfortable with based on your level of experience. Plain, simple, accurate descriptions of what you see are important. The goal is to paint a picture that ensures all readers will understand what you saw. It can be useful to draw analogies to common objects in reference to such things as color and texture. For example, one can clearly picture the following observations noted on a common dolphin:

*A circular lesion on the right side of the peduncle at the lateral midline, 15cm cranial of the base of the flukes. The lesion is 3.4cm in diameter, characterized by an outer, dark gray line encircling the lesion and a pale gray-white scar-like inner ring. The center of the lesion appears ulcerated and open, deep red/maroon in color, similar to raspberry jam.*

*500-700 ml. of port wine colored fluid in peritoneal cavity.*

### ***Images and video***

In addition to describing what you see, it is very important to document your observations through images and video. Digital, 35mm, and slide images are excellent means of capturing your observations. If possible, video taping or digitally recording images can also provide an outstanding record of your observations. If you don't have the means to photograph or video the animal, sketch what you see. These images are important in the human interaction evaluation. Documenting the evidence of HI, or the absence of that evidence, serves to support your HI evaluation and final diagnosis. In addition, proper documentation allows those analyzing or utilizing HI data in the future to better understand and vet your conclusions.

When documenting your examination, remember these tips:

- Photograph/video everything – even if you don't see marks
- Always use label and scale in all images – label should include Field #, date of stranding, species, organization; close up shots should include the name of the lesion/body part
- Be aware of shadows, glare and fingers – eliminate anything that obscures image and take images from different angles
- Draw and describe all marks

### ***Collecting physical evidence***

In some instances, human interaction cases may be considered enforcement cases in which law enforcement officers will pursue the interaction as a criminal or civil offense. For this reason, it is important to treat every HI case as a possible enforcement case. This means evidence should be collected and handled in a systematic manner. Evidence can include gear or debris removed from the animal, photos, and tissue samples, *etc.* Consult with your local law

enforcement officials to determine their requirements for evidence handling. In the United States, NOAA Fisheries Office of Law Enforcement handles infractions of the Marine Mammal Protection Act. They have specific evidence handling procedures and Chain of Custody protocols and forms. These measures ensure any evidence collected in the course of your investigation is admissible in court, should a legal case ensue. Basic guidelines for evidence handling include:

- Be sure to label all evidence and samples appropriately (see Suggested Sampling)
- Secure all evidence/samples, limiting access to a small number of known individuals
- When transferring evidence/samples to researchers or labs, be sure to maintain the Chain of Custody by utilizing a Chain of Custody form and instructions, available from your local law enforcement agency

### ***Tips for conducting an evaluation***

- **Develop a routine** - follow it for every exam
- **Document everything**
  - Photograph (include tag & scale in every image)
  - Measure marks/lesions (all dimensions)
  - Sample (especially for histopathology)
  - Collect other evidence and maintain chain of custody
- **Interact with others** - share unusual cases and lesions with other stranding personnel, fishery managers, and veterinarians
- **Understand and acknowledge confounding variables** - decomposition, scavenger damage, sunburn, and logistics are all things that make HI evaluation difficult. Never be afraid to score something as CBD

## **Recognizing Human Interaction**

In this section of the handbook, several common types of human interaction are presented in detail. Important definitions and descriptions are provided in conjunction with a summary of evidence and marks commonly observed. Examples are provided to illustrate these points and several full case studies are provided to illustrate the use of this protocol in recognizing, identifying, and documenting evidence of human interaction in stranded marine mammals.

### *Types of wounds/lesions observed*

**IMPRESSION** - an impression occurs when a line or net leaves an indentation, but does not lacerate or abrade the skin/pelt. Impressions left by net or line usually wrap around the leading and/or trailing edges of a fin, flipper or fluke. Impressions on the leading edge of an appendage may line up with a similar mark on the trailing edge.

**LACERATION** - a laceration is a cut into the skin or pelt. Net and line usually leave linear lacerations. These lacerations may be evenly spaced along an appendage (indicating net) and may be accompanied by impressions. Lacerations may also be caused by propellers, knives, and other blades.

**PENETRATING WOUND** - a penetrating wound occurs when a foreign object punctures or deeply penetrates the body, generally characterized by a small external wound and a wound tract that extends deep into the tissue and often into the body cavity. Sources of penetrating wounds include gaff, knife stab, spear, arrow, gunshot (especially bullet), *etc.*

**HEALED HI SCAR** - a healed human interaction scar is similar to a natural scar in pigmentation, but exhibits similar characteristics to the other types of lesions described here (e.g. linear scars on leading edges of appendages consistent with entanglement). It is as important to note healed HI scars as recent, unhealed wounds.

[NOTE: Evidence of HI, even if healed and not likely associated with the stranding event, should still be scored positive (YES) for HI.]

**ABRASION** - an abrasion occurs when gear or debris rubs an area and scrapes the skin/pelt without forming an obvious laceration. This often occurs with heavy line or twine entanglement, or when loose or trailing ends of gear/debris rub (abrade) parts of the body.

### **Fishery interaction**

Fishery interaction is probably the most subtle and varied form of human interaction that occurs. It is easier to recognize in cetaceans than in any other marine mammal groups because of the marks that are left in cetacean skin. In other marine mammals, it is difficult to determine if a fishery interaction has occurred without gear on or in the animal.

#### *Definitions*

To fully understand the complexities of fishery interaction, there are several terms with which the examiner should be familiar.


**GEAR:** any type of actively fished commercial or recreational fishing equipment (nets, buoys, line, hooks, lures, pots or traps, etc.).



**LINE** (above) is made up of many individual strands of a material (e.g. hemp, cotton, nylon, polypropylene). The strands are twisted into strands that are then twisted or braided into rope. Line is larger in diameter and heavier than twine (see below). Line can leave an impression similar to twine, only larger, but more often leaves an abrasion or 'rub' mark. It is used for moorings, towing, forms the float and lead line of nets and attaches buoys and anchors. Some gear uses primarily line, such as pot and trap fisheries. Line can be sinking (e.g. nylon), floating (e.g. polypropylene) or neutrally buoyant in seawater.

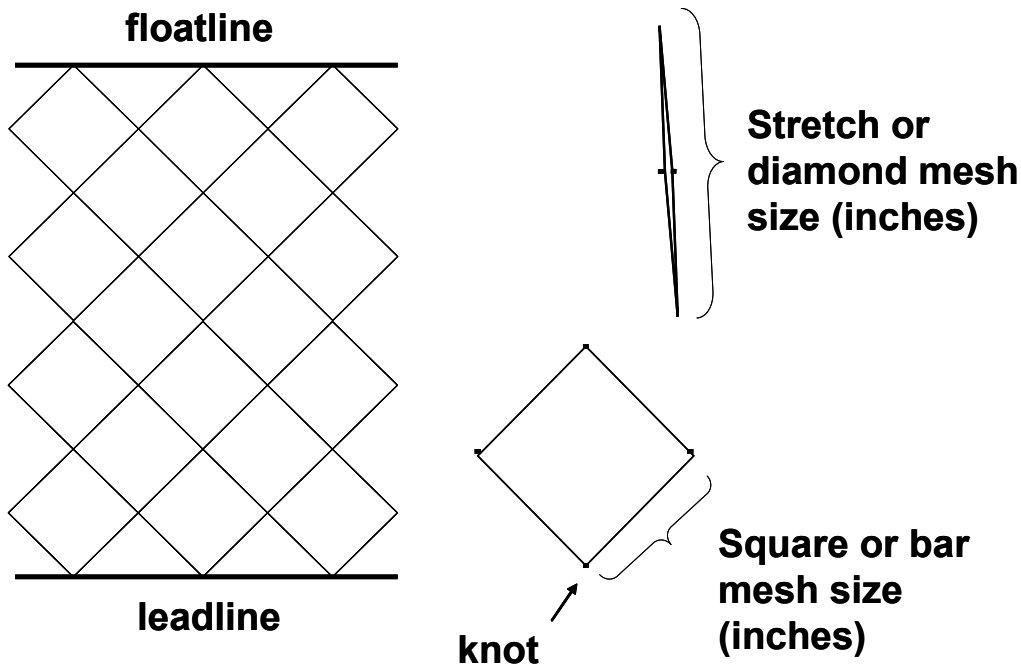
**TWINE** is small diameter line and can be multifilament or monofilament. Twine is constructed of various materials and is combined in different ways: some fishing gear is primarily made of NET which is comprised of one or more types of twine.

**MONOFILAMENT twine** (*right*) is a single, smooth strand of nylon that leaves a straight, narrow impression or laceration. Heavy (larger diameter) monofilament twine tends to leave impressions, while lighter (smaller diameter) monofilament twine tends to cut into the flesh and leave lacerations.

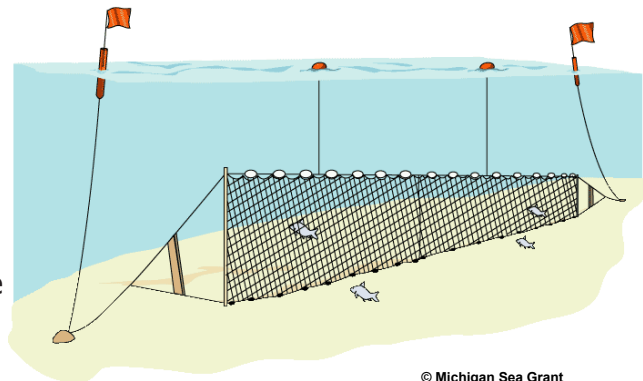


**MULTIFILAMENT twine** (*left*) is made up of multiple strands of material that are twisted or braided together. Multifilament twine can leave distinctive impressions (a series of parallel, angled lines or ovals).

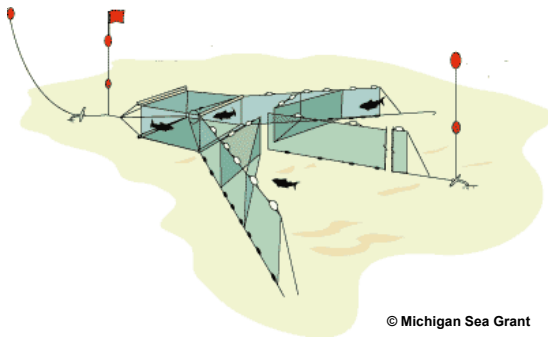
**NETS** (*below*) can be made of either monofilament or multifilament twine and have various characteristics: twine diameter, square mesh size (knot to knot), and stretch mesh size (diagonal between opposite knots of a mesh with one knot between).



**GILL NET** - (*right*) usually made up of 1 or more panels of monofilament net with a buoyant line at the top and a weighted line at the bottom. The mesh/twine size varies according to the target species and environmental conditions. Gillnets can be set at/in the upper, mid or bottom of the water column. Many gillnets are anchored on one or both ends with cement, chain or a standard anchor. Non-anchored gillnets are called drift nets. There is usually a buoy system on both ends. Animals can become entangled in the net, anchoring system, the vertical (buoy) line or the surface (buoy) system.

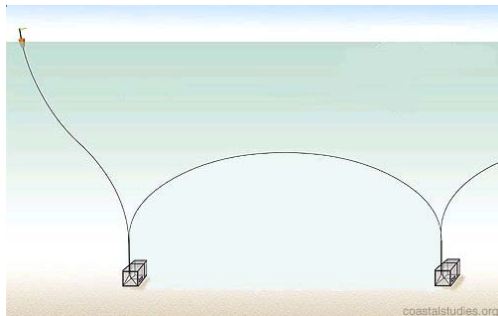
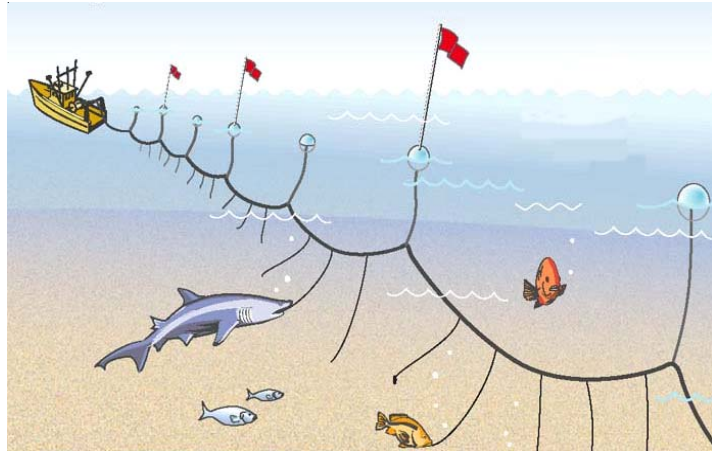






**FIXED NETS** (*left*) are often called fish traps. They include pound nets, weirs and other types. Fixed nets are staked, moored or anchored and are not moved. They usually have a straight leader line that directs fish toward the trap part of the net. These nets are usually made of heavy twisted twine and the mesh sizes vary in different parts of the net and in different areas. Animals can become entangled in the leader line, the anchoring system or in the fish trap.

**LONG LINE** - (*right*) is a commercial hook and line gear with numerous baited hooks on gangions attached to a central main line. The central line may be line, less often heavy monofilament, and the gangions are usually heavy monofilament. Some longlines are marked with light sticks which attract the target fish. Animals can become entangled in the central line, buoy lines, in the gangion and hook system, or ingest a hook or light stick.



**POT TRAWL** - (*left*) is used for crabs, lobster, whelk and other invertebrates as well as fish. When pots are attached together, the gear is called a trawl. The lines between the pots are called groundlines. The trawl may have one or more buoy lines. Animals can become entangled in the groundline, vertical (buoy) line or in the pot itself (usually going after bait).

Stranding responders should familiarize themselves with the types of fishing gear present in their area. Local fishers, fishery managers, enforcement officers and commercial fishing supply houses are good sources of information.


[FAO has produced a Fishery Manager's Guidebook (fisheries technical paper 424) which is available online at [FAO.ORG](http://FAO.ORG) for a \$26 fee. Basic gear types are described and illustrated in the book.]

#### *Evidence and marks commonly observed*

Entanglement in fishing gear can leave many different types of marks on marine mammals. These marks primarily occur on the edges of the head, appendages and peduncle and can generally be categorized as impressions, laceration, or abrasions.

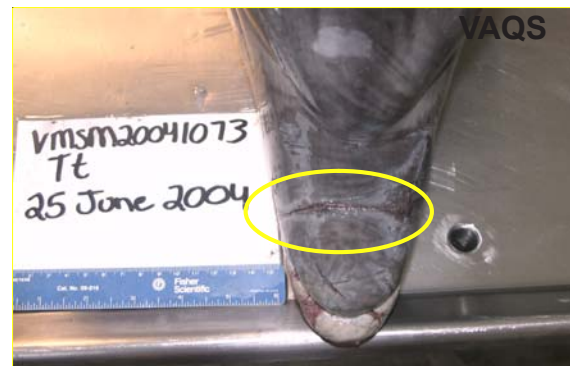
**Impressions:** As with all entanglement injuries, impressions are most often found on the head, leading and trailing edges of appendages. It is uncommon that an impression occurs only on a lateral surface (such as the thorax or side of the head, flukes or flippers) without a






Harbor porpoise (*Phocoena phocoena*) with a monofilament impression across the rostrum (above). Porpoises are notorious for NOT struggling once entangled in gear and often show only impressions.

corresponding mark on a leading and/or trailing edge. The diameter of the twine (twine size), the amount of struggle by the animal, and the shape of the affected body part all dictate whether monofilament twine or net produces an impression or a laceration. Impressions quickly disappear as an animal becomes desiccated or sunburned. When taking pictures of impressions, be careful of glare produced by lights and camera flash. Take images from several angles. Often an oblique angle without camera flash produces the best results.



MONOFILAMENT twine leaves a straight, narrow impression or laceration on the rostrum of a bottlenose dolphin (*Tursiops truncatus*) (above).

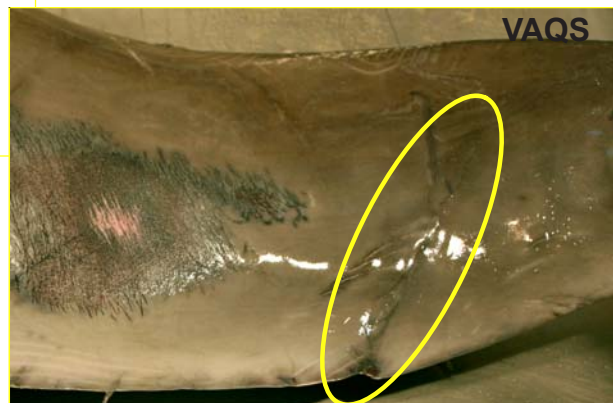


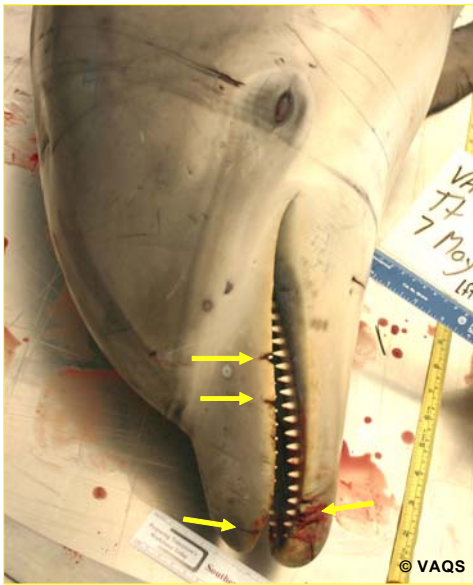
MULTIFILAMENT twine can leave an impression of a series of parallel, angled lines or ovals (left).

LINE can leave an impression of a series of parallel, angled lines or ovals larger than twine or abrasions (right).

**Lacerations** occur when the skin/pelt is cut. Net and line usually leave linear lacerations.

These lacerations may be evenly spaced along an appendage (indicating net) and may be accompanied by impressions. Lacerations associated with entangling forms of HI in cetaceans most often occur on the leading edges of appendages and on the rostrum and mandible.



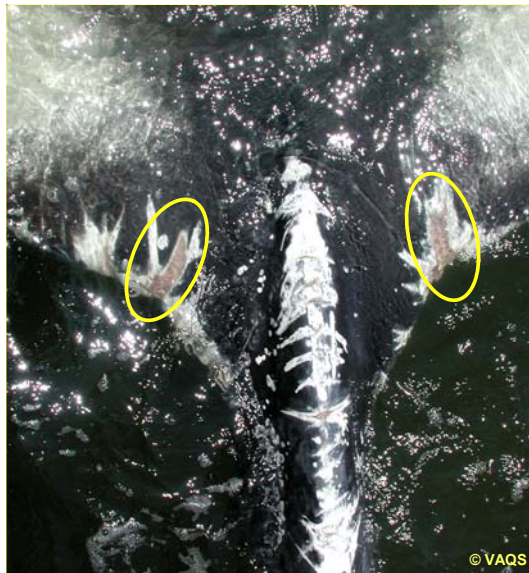


[Note the lacerations on the rostrum and mandible of the bottlenose dolphin pictured to the left.] The animal also had several impressions encircling the head. It may have hit a net, received the lacerations, then broken through the meshes until the head was caught. Sometimes the head goes through the net and the animal gets caught at the dorsal fin. In pinnipeds, the neck, appendages (especially between the claws) and in the mouth are the areas most susceptible to lacerations. A laceration can also be caused by a sharp instrument such as a knife.

Bottlenose dolphin (*Tursiops truncatus*) with fishery HI marks (left).

Harbor seal (*Phoca vitulina*) with entanglement marks (lacerations) around the neck (right).

**Abrasions** associated with HI tend to occur when heavy (thick diameter) twine or line are involved in an entanglement. They can also occur when gear is trailing on an animal and continually scraping against a body part. On pinnipeds, abrasions may occur around the neck or appendages. On cetaceans,



abrasions occur most often the appendages or on a lateral surface of the body affected by trailing gear.

Ventral view of flukes from a humpback whale (*Megaptera novaeangliae*) showing abrasions at the insertion of the flukes.

[Note the numerous healed HI scars (left).]


It is important to note that nets may leave different types of marks on an animal depending on the material from which they are made. Entanglement in a net may leave an impression on the animal, or may cause a laceration or abrasion. In many cases a combination of lesions may be associated with entanglement in a net. Nets made of monofilament may leave multiple impressions or lacerations, but each lesion is a straight furrow. Nets will usually leave a different set of marks than a single piece of twine. On cetaceans, look for 'X' shaped lesions (especially on the leading edges of appendages), and impressions of mesh or darker points along a linear impression indicating a knot. Net will often bunch up at the widest point of an appendage or on the body. Look around the head, at the insertion of the flippers and base of the dorsal fin for bunching. When a net is recovered from a stranded animal, it is important



to measure both the size of the overall net (dimensions of the float or lead line or number of meshes in height/width) and the size of each mesh (stretch and square size), and where in the gear the animal was entangled. It is also important to document marks left on the animal so those marks can be compared with animals that strand without gear. Often a heavily entangled animal will have few marks present once the gear is removed.

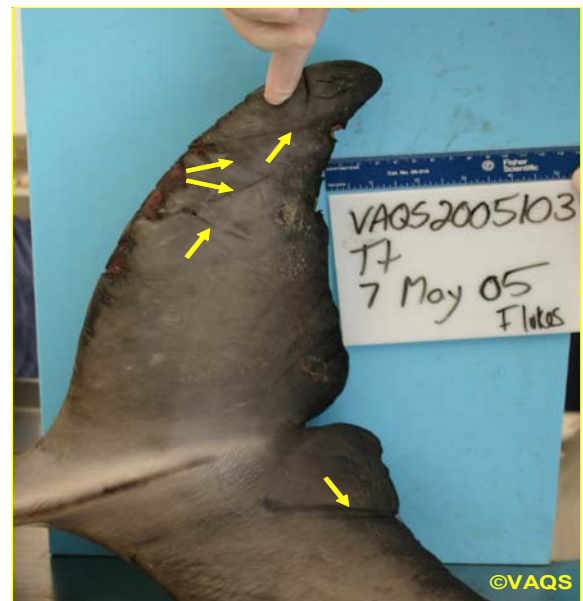### **Examples of signs of entanglement**

The following examples briefly highlight the most common entanglement injuries observed. Evidence of entanglement varies by the type of gear, the species involved, and the location and nature of the entanglement.



**Multifilament net impressions:** Skin of a bottlenose dolphin (*Tursiops truncatus*) showing multifilament net impressions. In Virginia this twine is consistent with a pound net (*left*).

**Monofilament net impressions:** Ventral flukes of a bottlenose dolphin (*Tursiops truncatus*) showing monofilament net impressions. Note the single furrow of the monofilament net versus the 'hash' marks made by the multifilament net (*below-right*).

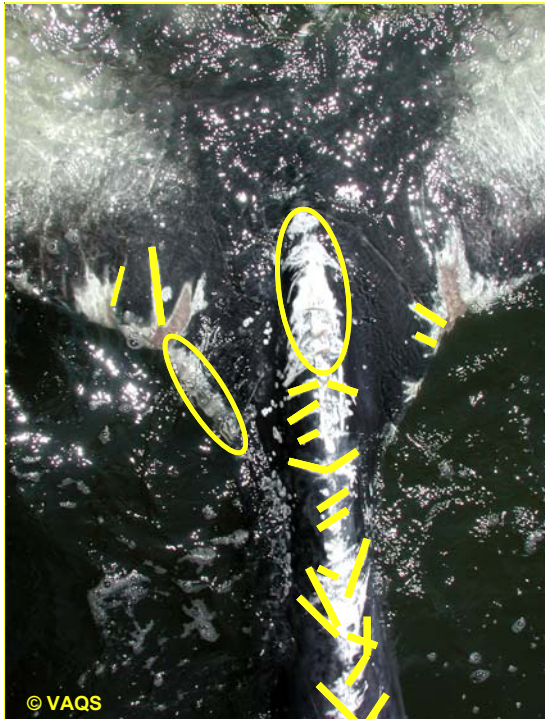


**Gear impressions (unknown):** The impressions on the tip of the fluke of this bottlenose dolphin (*Tursiops truncatus*) are thicker than most monofilament seen in the area (VA), but there are no hash marks within the impression to indicate the twine was multifilament. The lesion is likely from a net (see also the lacerations on the peduncle), but the twine type remains unknown (*left*).



**Gear impression/scar (unknown):** Peduncle of a bottlenose dolphin (*Tursiops truncatus*) showing an unknown mark possibly made by chain. The origin of this mark would be CBD unless the observer has experience with a lesion like this (left).

**Gear laceration (unknown):** The flukes of this bottlenose dolphin (*Tursiops truncatus*) have a laceration on the leading edge with granulomatous tissue indicative of a long-term entanglement. It is likely that whatever material caused the lesion was carried by the animal for a long time (weeks to months). We have seen twine and line of differing diameters cause this type of a lesion. Since there are also lesions on the other fluke and on other parts of the animal, it was scored as fishery, but the origin of this lesion was unknown (right).



**Line, healed scars:** A ventral view of humpback whale flukes (*Megaptera novaeangliae*) showing scars from lacerations and abrasions (left). [Note: while healed scars may not necessarily have contributed to the stranding event, documenting healed scars can provide information about the prevalence of HI that does not (immediately) result in stranding.]



**Longline fishery scars:** Short-finned pilot whale (*Globicephala macrorhynchus*) with scars from a longline fishery interaction (*right*).

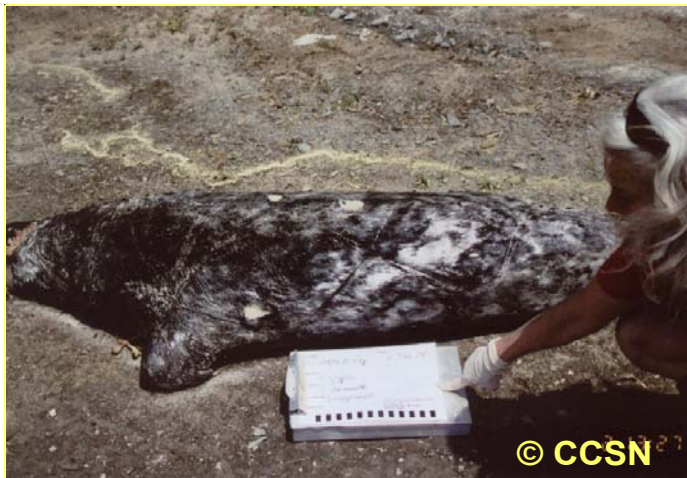
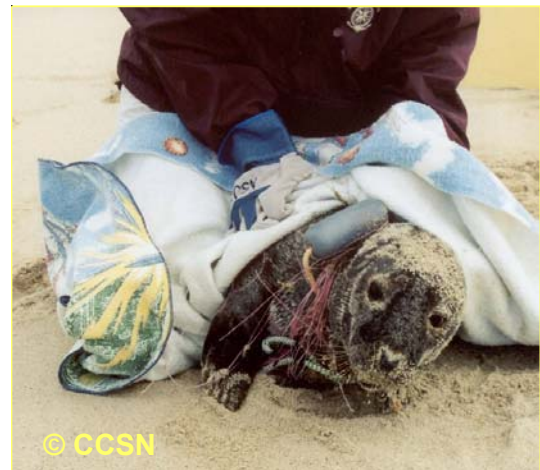
**Line, healed scars:** Fin whale flukes (*Baleanoptera physalus*) showing linear entanglement scars at the fluke insertion (*below*).

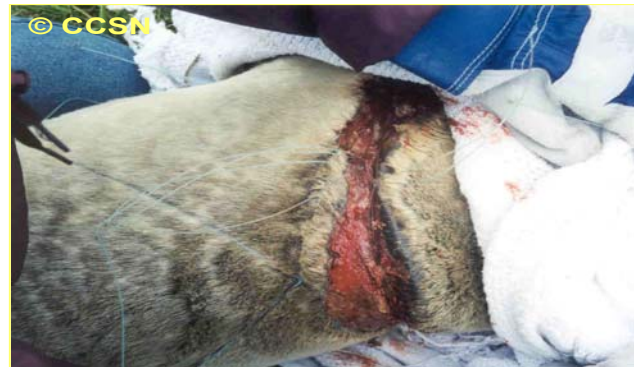#### Pinnipeds

**Twine impressions:** Live gray seal (*Halichoerus grypus*) with entangling gill net gear (Note the float; *right*).

Gray seals (*Halichoerus grypus*) with large mesh heavy twine impressions on the pelt, consistent with weir fishery (*below left and right*).



[Note: on pinnipeds and other marine mammals with pelts, fishery interaction is most obvious when gear is still attached. In some cases, gear will leave impressions and lacerations in the pelt that are obvious. Many times, there will be no evidence once gear is removed.]



**Monofilament gillnet (gear present):** Harbor seal flipper (*Phoca vitulina*) with fine twine net entanglement (above left). Neck of a harbor seal (*Phoca vitulina*) showing laceration from monofilament gear (above right).



Harbor seal (*Phoca vitulina*) with a neck entanglement in a pot buoy (left).

### **Fishery interaction summary**

Characteristics of entanglement are different in cetaceans and pinnipeds:

External evidence in cetaceans:

- Gear present
- Usually most prominent on the head and leading edges of appendages
- Linear impressions
- Linear lacerations
- Abrasions

Internal evidence in cetaceans:

- Subdermal hemorrhage and bruising
- Hemorrhage associated with lesions

External & Internal evidence in pinnipeds:

- Gear present
- Lesions on body (impressions, lacerations & constrictions)
- Subdermal hemorrhage and bruising
- Hemorrhage associated with lesions

There are times when an external exam may leave the examiner questioning whether signs of interaction are present (for example when only one or two marks are observed or when marks do not occur in the areas you expect them to occur). In these cases, findings that are consistent with fishery interaction support the case for HI. While these findings alone do not indicate interaction, they are consistent with HI.

Findings consistent with, but not indicative of, fishery interaction:

- Froth in lungs
- Evidence of recent feeding
- Robust body condition
- Other, similar cases at the same time in the same place



## Case Study #1

Perhaps the best way to understand how to examine marine mammals for signs of human interaction is to review case studies. The case study offered here is based on photo-documentation, data sheets and necropsy reports of a stranded marine mammal. Any animal in relatively good condition should be documented with enough detail to create a case study in the future by a party that did not examine the animal initially.

**Case History:** The carcass was reported to Virginia Aquarium Stranding Response Team (VAQS) by the general public on the afternoon of 27 October 2003. The carcass was transported to VAQS. It was photographed, measured and evaluated for HI then stored in a walk-in cooler until necropsy on 30 October 2003. Histopath samples were collected and submitted to the Armed Forces Institute of Pathology (AFIP), results were received in May 2004.

### External Description

**Condition code:** 3

**Preservation:** *fresh*

**Body Condition:** *not emaciated*

**Integument:** *normal*

**% Skin missing:** <10%

### Whole Body Exam:

- Appendages
- Pelt
- Body slit
- Gear/debris
- External pathology
- Natural markings
- HI lesions
- Scavenger damage

This dolphin was a very early condition code 3 (moderately decomposed). The mouth was not bloated, but had some odor and the genital slit was slightly bloated. The carcass was examined fresh and was not previously frozen. It was not emaciated. The skin (integument) was not sunburned or peeling and there were no gross abnormalities. There was no skin missing. All images were taken with the VAQS digital camera and were stored at the VAQS facility.



Note: all of these data are captured at the top of page one of the Human Interaction Evaluation data sheet.

When completing the data sheet, focus on lines 4-6 where the data sheet asks for external condition details: this section adds information critical to understanding the quality of the human interaction evaluation; information that could not be obtained from looking at the Level A data sheet.

*For example: condition code, which takes into account both the external and internal condition of the animal, can represent a broad range of circumstances. A code 3 (moderately decomposed) bottlenose dolphin in Virginia could be very close to pristine with only minimal bloating and odor. This animal may have its skin intact and may look very much as it did when it was alive. A code 3 bottlenose dolphin could also have almost none of its skin remaining or be severely sunburned and desiccated. The latter example may be very difficult to evaluate for subtle marks associated with some fishery interactions.*


**WHOLE BODY EXAM TABLE:** Before beginning a detailed exam, take a look at the whole animal. If possible, look at all angles and surfaces. Following your whole animal exam, check the most appropriate choice for each category. If you check YES or CBD, describe what you see in the *Comments* section on the next page, noting the appropriate line number. Indicate whether you collected an image of an area with a Y (Yes) or N (No) in the *Image taken* section. If you are unable to examine any areas, note the details in the *Comments* section. If there is evidence of predation or scavenger damage, circle the number(s) that correspond to the anatomical areas (in table below) where evidence is seen. If the area affected is not numbered, circle #30, and note the area in the table below (e.g. genital slit, umbilicus, tongue) and note details of the damage in *Comments*.

**Anatomical areas with signs of HI:**

rostrum  
mandible  
head  
flippers  
dorsal fin  
peduncle  
flukes

All signs of HI observed were impressions or lacerations consistent with monofilament net.

Marks on the mandible (lacerations) and on the rostrum and melon (impressions). Unaltered image is (*below left*) and marks are highlighted in the altered image (*below right*).



**PROTOCOL FOR EXAMINING MARINE MAMMALS FOR SIGNS OF HUMAN INTERACTION****Exam Information (fill in or circle most appropriate)**

- 1 Field #: VMSM 20031091 Species: *Tursiops truncatus*  
 2 Examiner: Sally Smith Recorder: Pam Jones  
 3 Date of exam: 27 Oct 2003 Condition code (at exam): 1 2 3 4 5 CBD  
 4 Preservation: alive fresh frozen frozen/thawed Body condition: emaciated not emaciated CBD  
 5 Documentation: digital print slide video Image disposition: VMSM  
 6 Integument: normal abnormal decomp/scaven % Skin missing: <10% 10-25% 25-50% >50%

- 7 Explanation of terms:  
 YES = I have examined the area and found signs of human interaction  
 NO = I have examined the area did not find signs of human interaction  
 CBD = I have examined the area and could not determine whether there were signs of human interaction (i.e. the part was missing, degraded, or signs were ambiguous)  
 NE = I did not examine the area  
 NA = this animal doesn't normally have that part (i.e. seals have no dorsal, dolphins have no rear flippers)

	WHOLE BODY EXAM	YES	NO	CBD	NE	NA	Image taken (Y or N)
8	Appendages removed / Mutilation (with instrument)		X				
9	Pelt removed / Mutilation (with instrument)					X	
10	Body sliced / Mutilation (with instrument)		X				
11	Gear/debris present on animal (includes tags)		X				
12	Gear retained (name & contact info in Comments)					X	
13	External pathology (pox, tattoo lesion, abscess, other)		X				
14	Natural markings (scars, tooth rakes, unusual pigmentation)	X					
15	HI lesions (fishery, gaff, gunshot, propeller, healed HI scar, brand)	X					Y

- 16 Predation/scavenger damage (circle all anatomical areas where damage hinders evaluation; numbers coincide with anatomical areas below): 17 18 19 20 21 22 23 24 25 26 27 28 29 30 NONE

										Origin of Lesion													
										Type of Lesion					Gear					Other			
DETAILED EXAM OF ANATOMICAL AREAS	YES	NO	CBD	NE or NA	impression / laceration	penetrating wound	healed HI scar	abrasion	other / CBD	twine / line	net	other / CBD	monofilament	multifilament	CBD	propeller	gunshot	other / CBD	image taken?				
17	rostrum/snout/palate	X				X					X		X						Y				
18	mandible/tongue	X				X		X			X		X						Y				
19	head	X				X					X		X						Y				
20	R front appendage	X				X					X		X						Y				
21	R body		X																Y				
22	dorsum/dorsal fin	X				X					X		X						Y				
23	L front appendage		X																Y				
24	L Body		X																Y				
25	ventrum	X				X					X		X						Y				
26	peduncle	X				X					X		X						Y				
27	R rear appendage					X													Y				
28	L rear appendage					X													Y				
29	flukes/tail	X				X					X		X						Y				
30																							





**Dorsal fin:** marks on the leading edge were lacerations and marks on the lateral fin were impressions (*original image-left & highlighted images-below left*).

**Right flipper:** the mark at the insertion of the flipper encircled the appendage and caused a laceration at the caudal insertion. Marks on the leading edge were lacerations (*original image-below & highlighted images-bottom*).



**Peduncle and leading edge of the right fluke:** marks on the peduncle were impressions and lacerations. Marks on the fluke were lacerations at the leading edge and impressions on the ventral surface (*below*).

**Ventral right fluke:** leading edge marks were lacerations and ventral marks were impressions (*below right*).



### Dorsal flukes (right).

The signs of human interaction noted on the specific body parts are captured in the *Detailed Exam of Anatomical Areas* section of the data sheet. To complete this section, examine the animal carefully starting at the head and working caudally down the right and then left side, finishing with the tail or flukes. For this section, indicate whether you observe any **SIGNS OF HUMAN INTERACTION** in each *anatomical area* by checking the YES, NO or CBD column. If you were not able to examine an area, check NE; if it does not apply to your animal, check NA (e.g.: pinnipeds do not have a dorsal fin). Be consistent; examine anatomical areas in the same order each time you do an exam.



For each mark you observe, proceed to the Type of Lesion columns and check all that apply. Once you determine the type of lesion, move to the Origin of Lesion section and check all that apply.

Every area that scores YES or CBD should have an **IMAGE TAKEN** with identifying information (field number, date of stranding, species, examiner, subject of image, etc.) and a scale (small ruler or something of known size). If film or disk space is not limited, take pictures of all areas. Note Y (yes) or N (no) in the **IMAGE TAKEN** column.

Every area that scores YES or CBD should have a comment associated with it. Number each **COMMENT** with the corresponding line number for that anatomical area. If you find lesions in an area not listed in the Detailed Exam table, add the area to line number 30 and complete the table as explained above.

### Internal Examination:

- **Skeleton examined** - no broken bones
- **Stomach examined** - intact fish in fore-stomach, parasites in main stomach, feces in intestine
- **Lungs examined** - bloody fluid in pleural cavity, left lung had white froth, right had pink froth and appeared hemorrhagic
- **No evidence of subdermal bruising or blunt trauma**
- **No other pathology observed** - mild lung worm, 30% fibrosis in pancreas, bloody fluid in abdominal cavity

**INTERNAL EXAM** - An evaluation is not complete without a thorough necropsy (internal examination). Some forms of interaction are only evident through internal exam (e.g. ingestion of debris or gear) and final interpretation may change if an animal with external evidence of HI is found to be suffering from disease, pregnancy complications, injuries, etc. Some observations support a diagnosis of HI (e.g. for fishery interactions-full stomach, froth in lungs) and others provide evidence for HI although nothing was noted externally (e.g. stomach full of man-made debris). Be sure to note the date of the internal exam in the **INTERNAL EXAM** box.

Example of completed Human Interaction data sheet for bottlenose dolphin VMSM20031090.

Field #: **VMSM 20031091**

INTERNAL EXAM Date of exam: <b>30 Oct 2003</b>		YES	NO	Partial	CBD	Image taken	Detailed Info (circle all that apply)
31	Internal exam conducted	<b>X</b>					Details in Comments section -use line number
32	Bruising/blunt trauma		<b>X</b>				Details in Comments section -use line number
33	Skeleton examined	<b>X</b>					Details in Comments section -use line number
34	Broken bones present		<b>X</b>				Associated tissue reaction: YES NO CBD
35	GI tract examined (circle contents)			<b>X</b>			<b>intact prey</b> partially digested hard parts only debris/gear empty other
36	Lungs/bronchi examined	<b>X</b>					Details in Comments section -use line number
37	Lung/bronchi contents	<b>X</b>					<b>froth</b> fluid air ( color: <b>white &amp; pink</b> )
38	Other pathologies noted		<b>X</b>				Details in Comments section -use line number

39 **Comments** (note line number from left margin before each comment):

35 - intact fish in fore-stomach, parasites in main stomach, feces in intestine  
- stomach examined; 8 whole fish (menhaden?) in forestomach; fluid in main & pyloric

36 - bloody fluid in pleural cavity, left lung had white froth, right had pink froth and appeared hemorrhagic

38 - mild lung worm, 30% fibrosis in pancreas, bloody fluid in abdominal cavity

40 **Signs of Human Interaction Observed:** **YES** NO CBD (transfer to Level A Datasheet)

41 **Stranding Event History/Circumstances:**

This animal stranded at a time of heavy pressure by commercial fishers on striped bass. Most of the fishing was conducted in the area just offshore of where the stranding occurred. This was one of 5 *Tursiops* strandings in 2 weeks that showed similar marks and stomach contents.

42 **FINAL HUMAN INTERACTION EVALUATION:** If you circled YES above (#40), evaluate the external exam, necropsy, carcass condition and circumstances surrounding the stranding event to answer the question below.

**How likely is it that the documented human interaction contributed to the stranding?**

0: Uncertain (CBD)

1: Improbable

2: Suspect

**3: Probable**

43 **Justification:**

Besides the lack of any other cause of stranding, this animal stranded at a time of heavy pressure by commercial fishers on striped bass.



**Comments** - The details of what you observe are required in this section. Provide comments for each item for which you checked YES or CBD. When describing lesions, include measurements (e.g. length, width, depth and distance between lesions), location (e.g. measurement from nearest landmark – 20cm caudal of the right flipper), color, shape and texture. Note the characteristics of the edges (e.g. jagged, straight or rounded) and the direction of linear lesions (e.g. wraps from leading edge of dorsal fin to trailing edge on left side). Number each set of comments using the corresponding line number for that row on the data sheet. Use extra pages if needed and be sure to note the animal's field number in the upper right margin. If this information is provided in the necropsy report or other data sheet, reference that material here.

**Signs of human interaction observed** - Review your exam notes, and circle YES if you observed any signs of human interaction on the animal. Circle NO, if you thoroughly examined the animal and did not find any signs of human interaction. Circle CBD if: (1) you did not examine the animal thoroughly, (2) decomposition or scavenger damage hampered the exam, or (3) you are unsure whether marks on the animal were caused by human interaction. This is an objective analysis. It does not take into account the animal's physical condition, the timing of the human interaction with respect to the stranding or the circumstances surrounding the stranding. TRANSFER THIS INFORMATION TO THE *SIGNS OF HUMAN INTERACTION* SECTION ON THE LEVEL A DATA SHEET. The dolphin had multiple linear lesions consistent with monofilament net on most appendages. **Signs of human interaction = YES**

**Stranding event history/circumstances** - Provide any information about the stranding event or circumstances surrounding the event that would be helpful in determining the HI diagnosis (i.e. fishing, drilling, oil spill, unusual mortality events, previous sightings of animal, unusual behavior prior to stranding, or other activities, etc.). Note any objective details provided by the initial reporter, these may be answers to questions you have asked (i.e. Was there any blood in the water next to the animal? What did it look or smell like when you first observed it? How was the animal positioned (belly up, on its side)?

**Final human interaction evaluation** - This section should be completed if you circled YES under *Signs of Human Interaction Observed* (#40). It should be completed after filling out the entire data sheet. This section is subjective and takes into account the animal's physical condition, necropsy findings, the timing of the human interaction with respect to the stranding, and the circumstances surrounding the stranding. Most importantly, it takes into account the evaluator's level of experience. If you have not conducted many evaluations or are not familiar with the region, you may be unable to make an accurate final evaluation. **Final human interaction evaluation:** Necropsy revealed no obvious pathology. The animal had fed recently and, based on its robust body condition, had been feeding consistently. It was robust and had few parasites. We felt certain (**probable = 3**) that the fishery interaction caused the stranding. Histopath results confirmed our final evaluation.

**Justification** - Provide a brief justification of your answer for the *Final Human Interaction Evaluation* score. Include information from all sources available to you. Use extra pages if needed, be sure to note the animal's field number on the top right margin.

### **Debris Entanglement**

Debris entanglements often involve live, free swimming animals that may be hard to recognize and capture despite obvious injury. Generally speaking, debris entanglement affects pinnipeds at a greater rate than cetaceans. Due to their inquisitive nature, pinnipeds will often investigate objects in the water, which can lead to entanglement, usually around the neck. Documentation of these cases is important and may lead to information about potentially harmful objects found in the marine ecosystem.

#### *Definitions*

**DEBRIS** - In the context of human interactions, debris refers to any non-fishery related items found in the water column (or on shore in the case of pinnipeds). Debris includes garbage, over-wash from vessels, and other sources. Almost any debris with a hole large enough for a pinniped to insert its head poses a risk of entanglement.

#### *Evidence and marks commonly observed (w/examples)*

The most common and obvious form of evidence is the visible object in which the animal is entangled. In most cases the gear remains on the animal for a long period of time, or even permanently, resulting in constrictive injuries as the animal grows. The constrictions can lead to deep lacerations, infection, and death.

Gray seal (*Halichoerus grypus*) entangled in an Aerobie Frisbee, (right).



California sea lion (*Zalophus californianus*) with plastic debris around neck (below left).



Elephant seal with plastic packing band embedded in neck (below).





### Debris/gear ingestion

Debris and gear ingestion are two forms of HI that usually exhibit no obvious external marks. Animals that have ingested indigestible foreign matter may be emaciated, but that is not always the case. Small amounts of debris may not affect normal feeding and digestion. However, some species seem more prone to debris ingestion. These include deep diving sperm whales and beaked whales. Some animals ingest foreign matter as a common, natural occurrence. Juvenile ice seals (harp and hooded) that strand in the northeast U.S. frequently ingest rocks or sand. These animals can die from the resulting gut impaction resulting from a natural behavior (i.e. not human interaction).

### Definitions

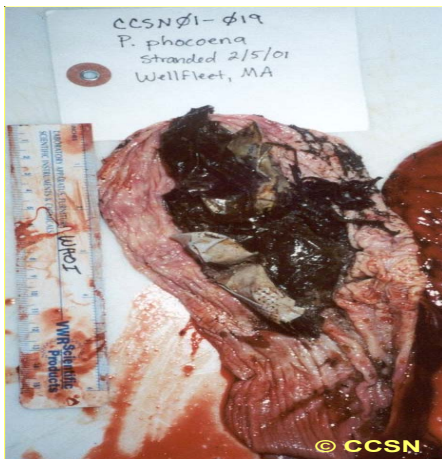The definitions of **DEBRIS** and **GEAR** remain the same as those described previously.

**INGESTION** - When an animal attempts to eat or swallow debris or gear, the result is HI classified as debris/gear ingestion. Ingested items may be found anywhere in the gastrointestinal tract: esophagus, stomach (all chambers), intestines, and colon.

### Evidence and marks commonly observed (w/examples)

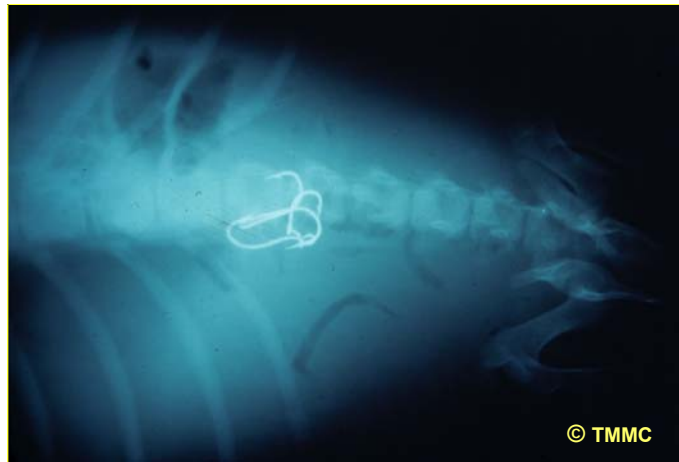
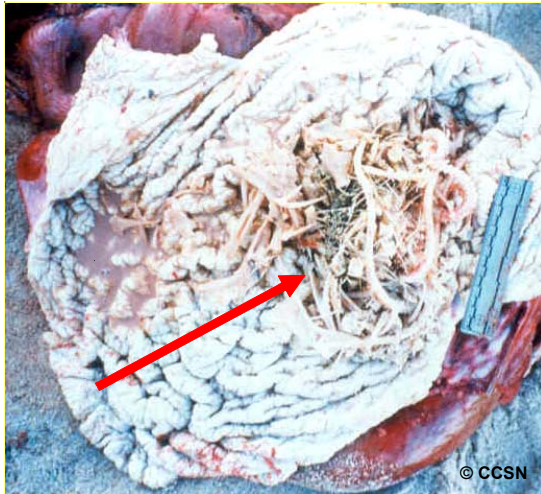
As previously stated, there are often no external signs of debris/gear ingestion. In some cases, individual animals may become emaciated if the debris has caused a blockage or other complication in the GI tract. However, in most cases the only evidence of HI is the debris or gear itself. In the case of live animals in a stranding or rehabilitation situation, the debris may pass through the GI system. The majority of the debris or gear ingestion cases will not be found until necropsy and examination of GI contents. All debris and gear should be photographed (be sure to include labels and scale), tagged, and archived as evidence of the HI.

Clear plastic, rock and feathers from harp seal (*Phoca groenlandica*) stomach (left). Potato chip bag from a pygmy sperm whale (*Kogia breviceps*) stomach (below).



Plastic bag and other debris in a harbor porpoise (*Phocoena phocoena*) stomach (left).

Radiograph of a California sea lion (*Zalophus californians*) showing hooks in the gut (right).



Gillnet found in main stomach of a long-finned pilot whale (*Globicephala melas*). The net was associated with an abscess in the stomach (left).

### ***Evaluating Debris/Gear Interaction Cases***



Harbor porpoise (*Phocoena phocoena*) above (right) stranded alive and was later euthanized. Upon necropsy, plastic debris was discovered in the forestomach (left).

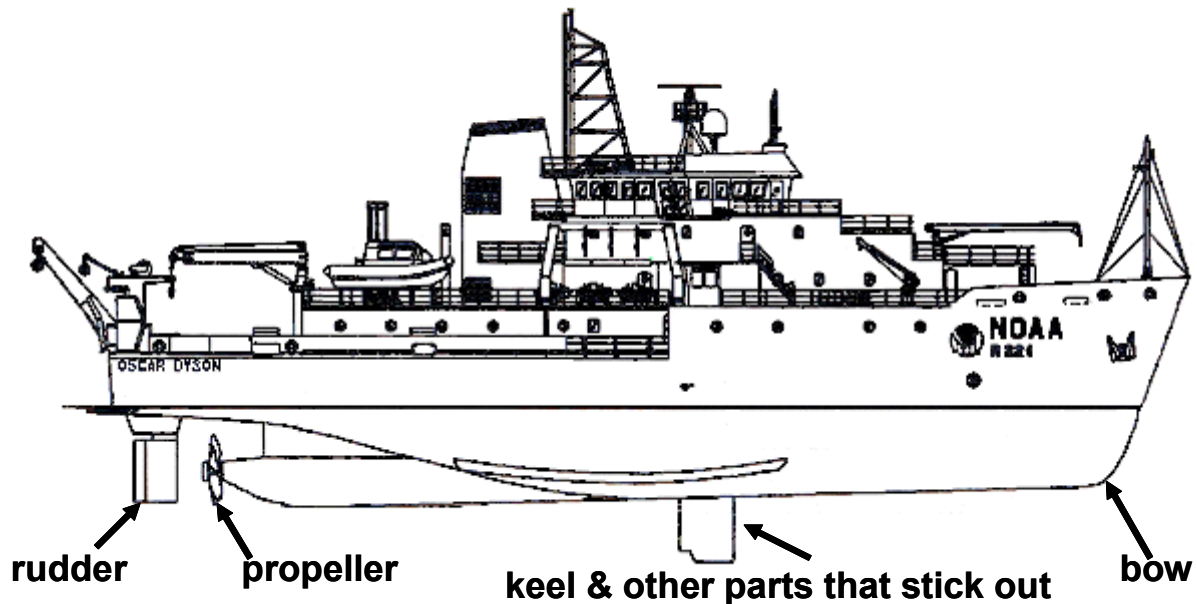
**Signs of HI = YES**

**Final Evaluation = 2 (suspect)**

Reaching a final evaluation can be problematic in debris and gear ingestion cases, especially when the amount of foreign substance is small. In this case, the harbor porpoise stranded alive, but emaciated. After hours in rehab, it began exhaling worms and froth from the blowhole. It was euthanized and necropsied. Plastic debris was found in the stomach, but not blocking sphincters. Was plastic ingestion a cause of or a symptom of illness? It was unclear whether the animal was already emaciated and compromised when it ingested the plastic (much like ice seals do with sand and rocks in New England) or whether it ingested the plastic and was then compromised because of the ingestion. The Final Evaluation reflects this uncertainty with a score of 2 or Suspect.

### **Vessel Interactions**

Vessel interactions occur in several ways. Sharp parts of vessels (often propellers) can cause sharp or penetrating trauma that is obvious upon external examination (in the form of characteristic lacerations). The bow, keel and other blunt parts of vessels can cause blunt trauma that leads to internal injuries (subdermal hemorrhage, edema, and broken bones), often without any external signs. However, some blunt traumas may leave abrasions externally. Vessels can inflict very different external wounds, depending on the vessel size, what part of the vessel is involved (keel, propeller, bow, etc.) and what part of the animal is involved. It is imperative that a thorough internal exam accompany a finding of vessel interaction, to determine whether the strike occurred before death.



#### *Definitions*

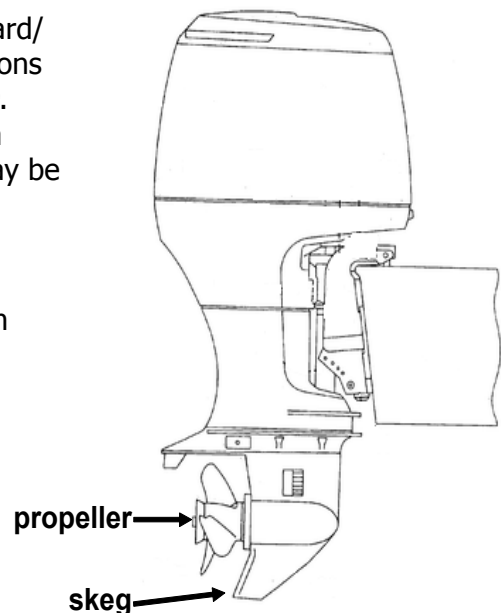
Some parts of vessels can result in sharp trauma injuries (propeller, rudder and other parts that stick out) while other parts result in blunt trauma injuries (bow, hull and other blunt parts; *above*).

Outboard engines and outdrives (or lower units) of inboard/outboard engines usually result in sharp trauma interactions from the propeller or skeg (fin below the propeller; *right*). The hulls of small vessels can also result in blunt trauma damage, especially in shallow water where an animal may be pushed against the substrate by the hull of a boat.

#### **SHARP TRAUMA** (propeller strike)

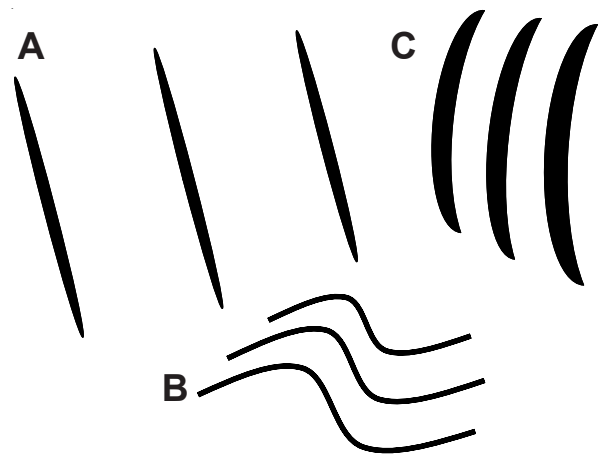
Propeller wounds (or prop strikes) are the most common sharp traumas observed in vessel interactions.

[NOTE: Propeller lesions vary by different styles and sizes of propeller(s). The length, depth and spacing between lesions can provide information as to the type of propeller and vessel, as well as the vessel's direction of travel and speed.]





Propellers usually leave deep, roughly parallel lacerations (*right*). Lesions can be (A) straight, (B) Z or S-shaped, (C) curved, or open in the middle with thin trails (not illustrated). Large vessels may bisect an animal. Propellers have different sizes, numbers of blades, pitch, and configurations. Vessels can have a single propeller or two propellers separated by varying distances. Two propellers can be mounted on the same shaft rotating in different directions. The latter configuration causes very unusual diamond or 'X' shaped lesions, unlike those at right.



Sharp trauma from vessel interactions can be recognized by some of their common characteristics:

- Usually more than one wound
- Linear or slightly curved lacerations
- Usually found as a series of parallel cuts
- Often in a corkscrew or sequential pattern

When documenting propeller wounds (as well as cuts or wounds from any other source), it is important to gather as much data as possible about the wounds. These details may be useful in determining what type of vessel may have caused the wounds. The following tips will guide the examiner in recording and documenting these events:

- Number the lesions from head caudally
- Note the length, width & depth of each cut
- Note the distance between each cut
- Note the tissues affected (blubber & muscle, ribs, organs, *etc.*)

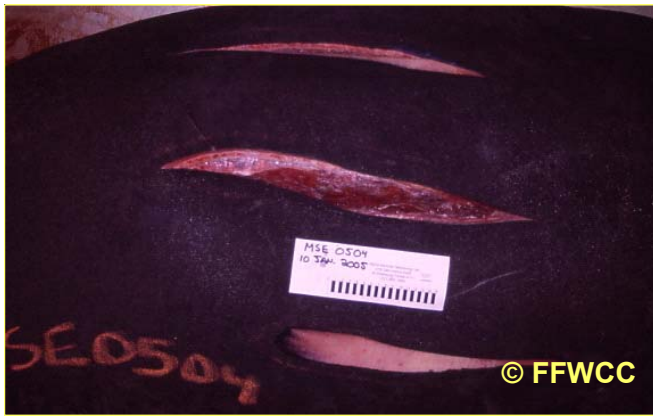*Evidence and marks commonly observed (w/examples)*

Large vessels with large propellers tend to create straight line cuts that are far apart like the 3 cuts on this humpback whale (*Megaptera novaeangliae*). Large propellers can even bisect an animal (*right*).



Smaller propellers make discrete cuts that are closer together than they are long. Smaller propellers may create shallow lacerations like the ones on the gray seal (*Halichoerus grypus*) that penetrate the blubber and outer muscle layer (*left*).





Manatee image with parallel prop wounds, slightly Z-shaped (left).

Adult gray seal (*Halichoerus grypus*) with large propeller injury. Not seen in this photo is the sequence of 8 smaller, curved, sequential lacerations. This animal was observed being struck by a recreational boater. It bled out and died quickly due the deepest wound, which had penetrated a major artery (below).



This gray seal (*Halichoerus grypus*) has two distinct propeller wounds (appearing as inverted triangles in this photo). There is also evidence of peri-mortem or post-mortem shark predation. However, the clean lines of the prop wound are still evident, amputating the right rear flipper (left).

Propeller wounds penetrating into the abdominal cavity of a harbor seal (*Phoca vitulina*). There are two smaller, linear lacerations in line with the larger abdominal wound (one visible here). The abdominal wound also appears to have been enlarged by a shark bite. This is not uncommon near Monomoy National Wildlife Refuge in Chatham, MA where there is a confluence of seals, recreational and commercial boaters, and a seasonal shark population. Injured, bleeding seals attract sharks. These bites can often destroy some or all evidence of HI (right).





## Evaluating Sharp Trauma Vessel Interaction Cases



This gray seal (*Halichoerus grypus*) has four parallel lacerations penetrating deep to the bone on the caudal dorsum, to the right of the dorsal midline.

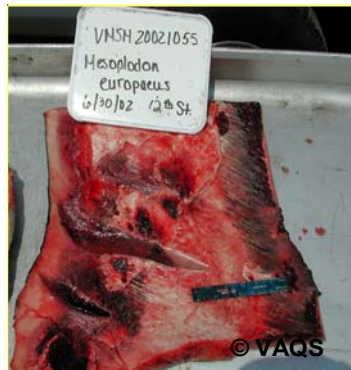**Signs of HI = YES**

**Final Evaluation = 3 (probable)**

This dead gray seal (*Halichoerus grypus*) was reported to the stranding network on 9/8/04 as a seal hit by a boat, with prop wounds evident. The carcass was collected by the Dept. of Natural Resources and transported to a landfill, where the carcass was examined on the same day. A partial internal exam (limited due to state of decomposition and logistical considerations) revealed subdermal hemorrhage in association with the wounds. An incomplete dissection revealed one broken rib also associated with the wounds. Evidence of HI (vessel strike) was present on the animal and observed muscle hemorrhage indicated that the propeller strike occurred before death and was the apparent cause of the stranding. Signs of human interaction=YES. Histopathology findings in conjunction with the details from the individuals reporting the event support a finding of 3=Probable that the HI caused this stranding.

Dorsal propeller wounds on a live stranded Gervais' beaked whale (*Mesoplodon europaeus*). This animal was observed alive in the surf. The injury obviously occurred pre-mortem, but documentation is still important (*far right*).

Of the four lacerations, the shallowest was closest to the head and did not penetrate the blubber. The other three lacerations penetrated through the blubber and into the epaxial muscle (*right*).



Manatees are the poster children for vessel strikes. Many animals survive one or more vessel strikes and bear the scars of those interactions because of their thick hides. This animal is named Manx and lives in Southwest, FL (right).



© Dee Grant- FFWC

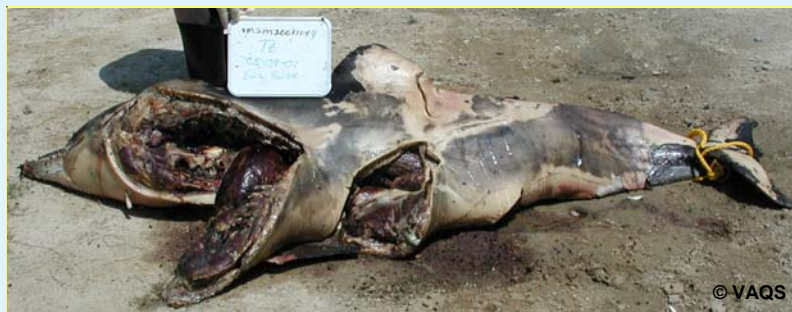

This is another example of a vessel strike on a Florida manatee (left). Note the serial nature of the lacerations characteristic of a propeller strike. There are nine main wounds that vary in depth into the underlying tissue. Also note the perpendicular laceration at the ventral edge, possibly caused by the rudder or skeg of the engine.

### ***Evaluating a Decomposed Sharp Trauma Vessel Interaction Case***

This was a lone sociable bottlenose dolphin (*Tursiops truncatus*) that had been observed begging from boats. The carcass was discovered as a code 4 (severely decomposed) with obvious propeller damage. The size and orientation (corkscrewed around the body) of the lesions suggest an interaction with a fairly large vessel.

Despite suspicion that the dolphin was struck while it was alive, we could not determine whether any hemorrhage was present and the tissues were too decomposed for histopathology.



© VAQS

**Signs of HI = YES**

**Final Evaluation = 0 (cannot determine)**

This dolphin had been observed alone in a river for over 6 months. It was reported to be begging from boats and several calls from the public suggested that it was feeding on discarded bait from crabbers. Although, the reported behavior of the animal indicates that it would have been susceptible to vessel strike because of its inclination to approach boats, due to decomposition we were unable to determine the likelihood that the HI contributed to the stranding, Final Evaluation = 0.



## BLUNT TRAUMA

Blunt trauma occurs when an object (usually large or heavy) strikes a victim with enough force to cause internal damage, often with very little external damage. When a marine mammal interacts with the hull or other blunt portion of a vessel, the interaction often results in blunt trauma that can be fatal. The presence of unusual lumps, bumps, dents or misshapen areas on the carcass can be an indication of blunt trauma. Also look for blood in the eyes, mouth and nares. Although external signs of blunt trauma are not always evident, when present they may include:

- Abnormal appearance of body shape (lumpy or misshapen profile)
- Swelling
- Abrasions and/or associated hemorrhage and bruising

Internal evidence of blunt trauma is always present and serves as the primary diagnostic indicator. Internal evidence can include:

- Subdermal hemorrhage and bruising (pink tinged blubber, muscle tissue with a deep maroon/purple color and gelatinous texture)
- Edematous tissue
- Broken bones
- Organ damage

In almost all cases, blunt trauma is difficult to detect without a necropsy. In large cetacean carcasses, blunt trauma may result in one area decomposing faster than others internally. Areas of blubber and/or muscle affected by the trauma may be liquefied while other adjacent muscle and tissue may appear normal. In fresh carcasses, organs may appear fractured or broken bones may cause organ damage. In these cases, look for evidence of hemorrhage associated with fractures and organ tears.

Fin whale carcass in Virginia with a lesion later found to be associated with blunt trauma. The yellow arrow indicates the location of the lesion (*below left*). A close-up examination of the lesion reveals an abrasion with missing skin and an area that extends deep into the abdominal cavity. The whale is beginning to off-gas (*below right*).



© VAQS



© VAQS

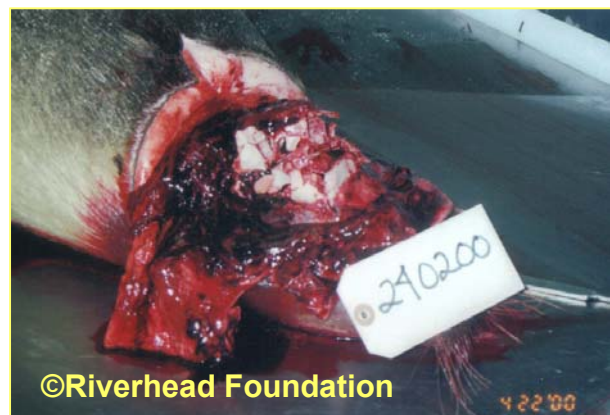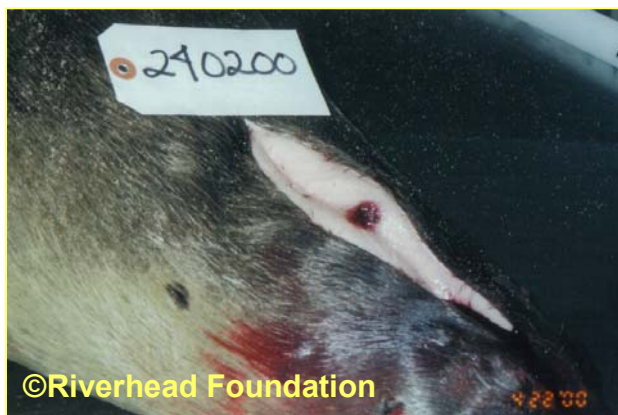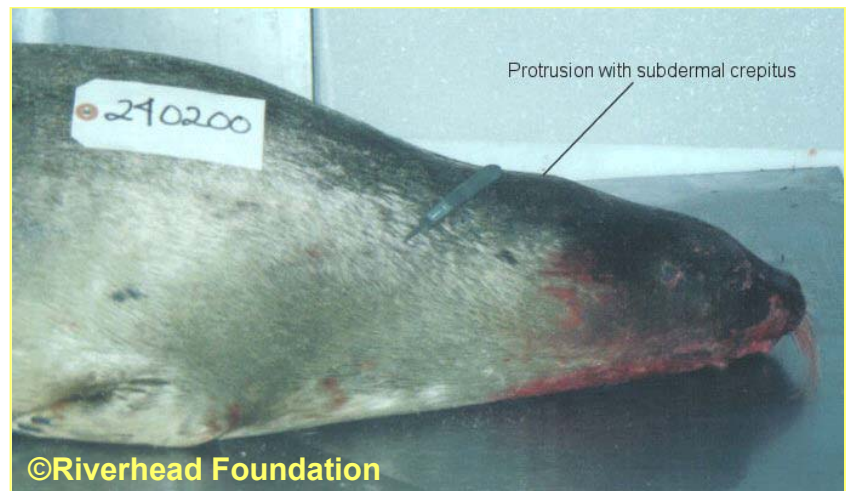
When the blubber was removed from the side of the carcass, muscle below the lesion was very dark red and liquefied while muscle adjacent to the area was lighter in color and normal texture. Transverse processes of the vertebrae were broken in this area. The yellow bracket indicates the area where muscle was liquefied (*right*).



*Evidence and marks commonly observed (w/examples)*

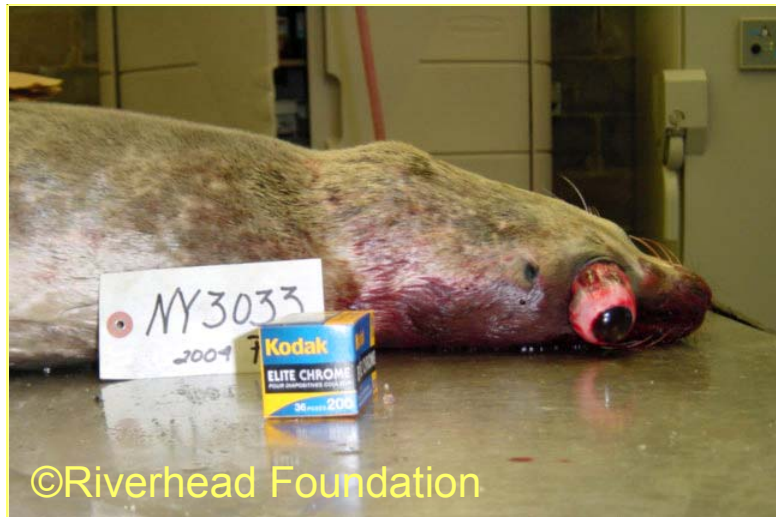*Pinnipeds*

Carcass of a seal rehabilitated and released by the Riverhead Foundation in Long Island New York. Note the slight swelling on the dorsal surface of the neck and the bloody fur around the head. There is no obvious laceration or penetrating wound (*below right*). When the animal was examined internally, initial cuts revealed bloody blubber at the site of the swelling (*bottom left*). While the trauma did not result in broken skin, the internal damage to the head and skull was massive, as shown here with the flesh reflected back to reveal severe hemorrhage and skull fracture (*bottom right*). The blunt trauma and case history suggest that this was likely the result of a vessel interaction. The seal was possibly hit by the bow of a vessel resulting in the traumatic head injury.





This harbor seal (*Phoca vitulina*) was recovered from a roadway in New York where a seal/vehicle interaction obviously occurred (bloody tire tracks in the road on either side of the seal). Note the misshapen appearance of the head and neck and the bulging right eye (right).



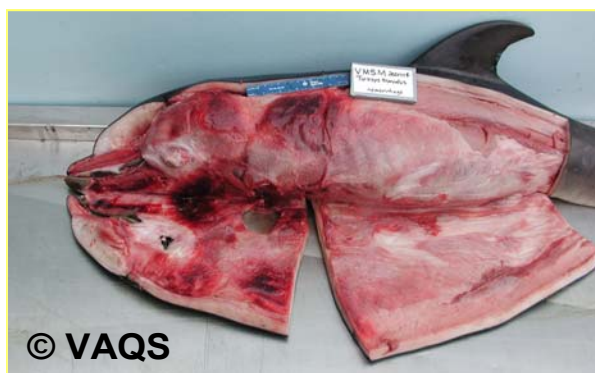Although the eye appears normal in this view showing the left side of the same seal, the head and neck area are clearly misshapen. Cases such as these where the cause of the trauma is obvious provide an opportunity to document known HI. These cases help other responders in the field who may not have a 'crime scene' that provides clues to the cause of the trauma (right).



All cases of blunt trauma are not necessarily the result of human interaction. This bottlenose



dolphin calf (*Tursiops truncatus*; left) appears normal with the exception of a small dent on the left side of the head and some tooth rakes.



When the blubber was reflected back, discrete areas of hemorrhage were obvious. Although this was a case of blunt trauma, it was not due to human interaction. This was a case of infanticide where adult *Tursiops* inflicted the wounds seen on the calf. Aggressive attacks and other natural events (such as birth) can result in blunt trauma, so take care not to jump to conclusions. Collect your data objectively, then analyze all findings (left).



## Case Study #2 – Vessel strike with blunt trauma

Sei whale (*Baleanoptera borealis*) in Virginia showing lesions on the right flank (below).



### Case History:

This sei whale (VMSM20031006) was reported floating in the Norfolk harbor on 19 Feb 2003 by the US Coast Guard and was towed to a military beach for necropsy. The necropsy was completed on 20 Feb 2003.

### External Description

**Condition Code:** 3

**Preservation:** fresh

**Body Condition:** not emaciated

**Integument:** normal

**% skin missing:** <10%

The left side of the whale showed no external lesions (above right).



There were circular rub marks, and a linear lesion, on the ventral right mandible (below right).

The whale was in fairly good condition with minimal bloating; it was marked as moderately decomposed (code 3). It was fresh when examined and was not emaciated. With the exception of the noted abrasions, the skin was intact and normal.



The location of the linear abrasion and the abraded areas on either side of the linear mark indicate that the whale was most likely pinned against and wrapped around the bow of a ship. Although an exact vessel was not identified, the whale probably floated to the surface when the ship slowed or reversed to dock. An external examination alone allows us to score the carcass as YES for Signs of HI. However, without an internal exam we cannot determine whether the whale was alive at the time it was hit.

### WHOLE BODY EXAM:

The whole body exam, which can be challenging with large whales, revealed only the marks shown in the first photograph. The whale had a laceration perpendicular to the body axis from the dorsal midline to below the right flipper; the right flipper had no obvious injury. On either side of the laceration, there were large areas where the skin was abraded. The ventral and left sides had no obvious lesions.

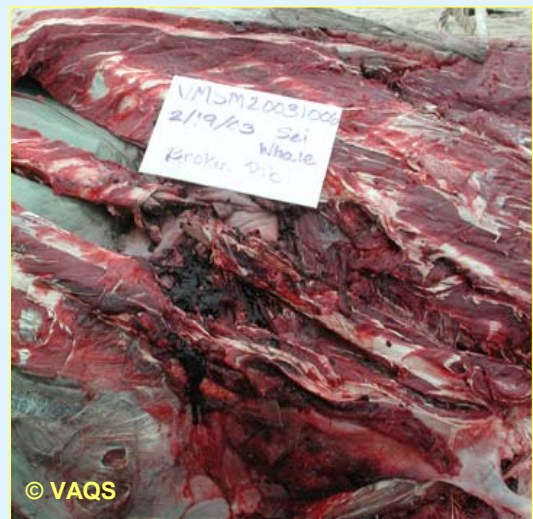The initial exam centered on the tissue proximal to the linear lesion and abrasions.

### Detailed anatomical exam:

#### INTERNAL EXAM –

Making cuts to remove blubber and examine underlying tissue (*right*).

We began the internal exam by removing the blubber from the right side of the carcass. Although there was an obvious external abrasion and laceration to the right thorax, internal exam showed no subdermal hemorrhage beneath the wounds. There was no tissue reaction to indicate that the whale was alive when hit. We continued the exam by stripping the blubber on the left side of the carcass.



On the left side of the carcass, we found bruising and hemorrhage associated with underlying rib fractures proximal to the left flipper (*above left*). Two ribs were broken level with the mid-flipper on the left side (*above right*).

There was obvious hemorrhage near the left flipper which was associated with the two broken ribs. The hemorrhage was deep into the muscles, including the intercostals (between the ribs). We sampled hemorrhagic blubber and muscle for histopathology and collected the broken rib ends.



Although the external evidence of ship strike was on the right side of the body, the internal injuries with associated clotted blood and edema were on the left side. Other than these lesions and some intestinal parasites, the animal appeared to be healthy.

Grossly, it appeared that the animal had been hit on the left side when it was alive. The body was probably trapped by the force of the vessel and then rolled onto the right side, likely resting against the bulb on the bow of the ship, resulting in the external abrasions observed.

**Signs of human interaction observed** - There were obvious signs of abrasion from a large vessel on the right side of the whale. Signs of Interaction = YES

**Final human interaction evaluation** - The external lesions on the right side appeared to be post-mortem. The left side showed obvious subdermal damage consistent with pre-mortem blunt trauma. We felt confident (probable=3) that the whale was hit while it was alive. Histopathology results later confirmed the animal was alive when struck.

**Justification** - The laceration and abrasions on the right side were consistent with the whale being carried on a ship's bow for a period of time. Histopathology results showed that the internal injury on the left side occurred before death, indicating that the whale was probably struck on the left and rolled so that the right side faced the bow. It was likely carried into port this way and floated off when the ship slowed or changed direction. There were no other obvious pathologies other than a heavy parasite load in the intestines.

### ***Other Types of Human Interaction***

There are numerous other types of human interaction that affect marine mammals. This section highlights some of the more common interactions, providing insights into recognizing other types of HI.

#### ***Gunshot and other penetrating wounds***

Penetrating wounds are generally characterized by a small external wound and a wound tract that extends deep into the tissue and often into the body cavity. However, some penetrating wounds, such as those created by shot gun pellets at close range, can result in larger wounds. Also, when a projectile passes through a body completely, it may leave an exit wound that is substantially larger than the entrance wound. Sources of penetrating wounds include gaff, knife stab, spear, arrow, gunshot (especially bullet), etc. Radiograph (X-ray) is the best way to confirm if an object or objects (bullet, shot, arrow tip) are imbedded in the wound. On necropsy, follow track of lesion and look for entry and exit wounds; exit wound from bullet is usually larger than entry. Collect shot or bullets and store as evidence for enforcement.



© CCSN

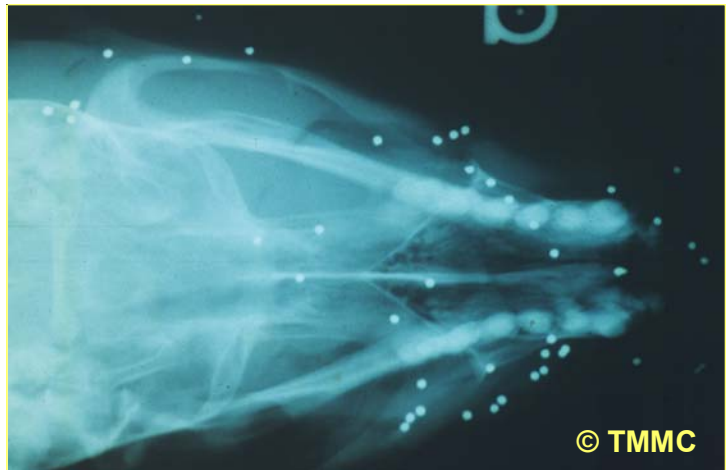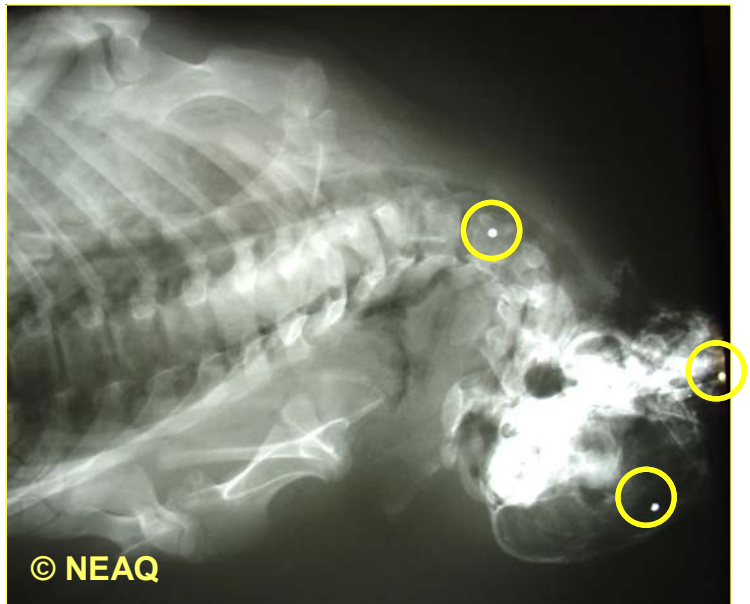
*Evidence and marks commonly observed (w/ examples)*

Harp seal (*Phoca groenlandica*) with an irregular wound to the head (*left*).



Radiograph of the seal pictured previous page. The seal most likely sustained a shotgun wound from close range as evidenced by the skull damage (right).

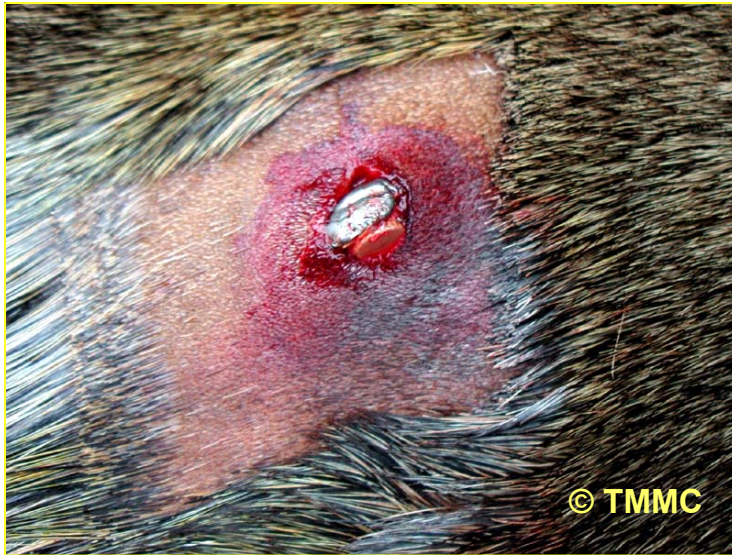California sea lion (*Zalophus californianus*) with bullet imbedded in forehead between the eyes. This animal survived (below).



Radiograph of a California sea lion (*Zalophus californianus*) with shotgun pellets in the head. The image shows the skull intact with numerous pellets imbedded in the tissue, suggesting a greater distance from the shooter (above).



Harp seal (*Phoca groenlandica*) with an irregular shot gun wound to the head (left). Radiographs revealed multiple pellets lodged in the tissue and bone.



Close view of a bullet wound in a California sea lion (*Zalophus californianus*). Note the fur has been shaved to expose the wound before surgery to remove the bullet (left).

California sea lion (*Zalophus californianus*) with an arrow penetrating the neck. The animal may have survived for some time with the imbedded arrow considering its emaciated condition (below).

### **Harvest/Mutilation**

Mutilation is usually a post-mortem interaction. Its presence, however, is important to note in light of the Marine Mammal Protection Act. In addition, some mutilation is conducted by fishers in an attempt to disentangle animals from their gear, to sink a carcass in hopes that it will not strand, or to conceal an interaction.



### **Definitions**

Mutilation is the intentional cutting or slicing of an animal or carcass. Mutilation generally involves the use of some type of knife or hand held blade and can result in several common types of lacerations and amputations including:

- Body sliced
- Appendages removed
- Body stabbed
- Gutted

Body slices are the easiest type of mutilation to determine. Appendage/head removal can be problematic due to scavenger damage. Look for knife cuts on bone and areas where tissue is cleanly sliced in a straight line. The harbor porpoise (*Phocoena phocoena*) pictured (next page) is typical of the mutilation observed in cetaceans in more recent years. By removing appendages, fishers 'erase' all net marks, and the carcass can be scored as a mutilation, but not as a fishery interaction.

Scavenger damage can hamper the observer's ability to determine if mutilation occurred. While the tissue on the head, flippers, and flukes may have been removed with an instrument, scavenger damage to the cut surfaces (very attractive to gulls and other animals as an easy meal) makes it difficult to assess.



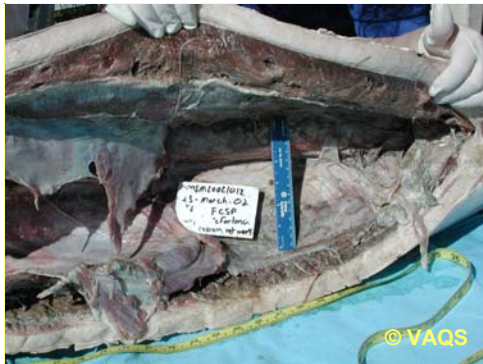### Evidence and marks commonly observed (w/examples)

#### Cetaceans

Stranded harbor porpoise (*Phocoena phocoena*) from Virginia with abdominal slice (top right) and appendage (dorsal fin) removed (below right). Since there is no legal harvest in Virginia, this activity is considered mutilation.



This bottlenose dolphin (*Tursiops truncatus*) stranded in Virginia with a body slice from larynx to anus. What was unusual about this mutilation was that, in addition to the mutilation, all organs were removed (below).

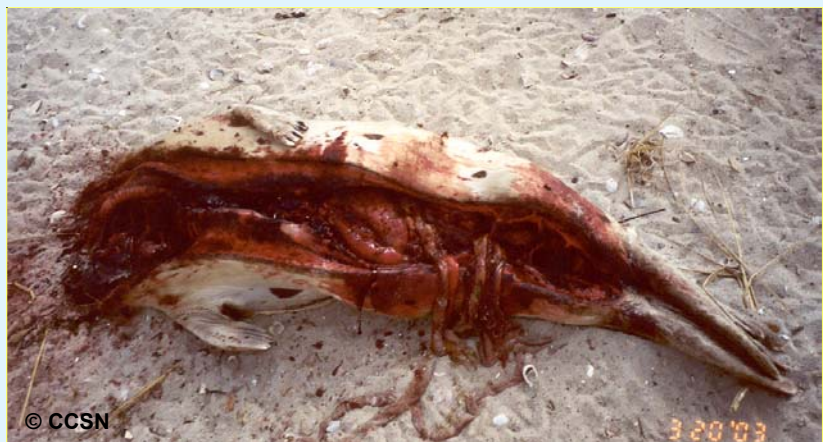

#### Pinnipeds

Similar to cetaceans, pinnipeds are subject to numerous types of mutilation. This is sometimes the result of harvesting tissues (usually reproductive organs) for illicit sale. Similar to cetaceans, pinnipeds may also be subject to mutilation from fishers attempting to disentangle carcasses from their nets.

### Evaluating a Harvest/ Mutilation Case

In some areas of the United States, it is legal for some people (particularly native communities) to harvest marine mammals or marine mammal parts for a variety of uses. In most of the mainland US, harvest of live marine mammals or parts of dead





marine mammals is illegal without appropriate authorization, and never for resale. In some cases, carcasses are mutilated without any obvious attempt to harvest. In these cases, the damage done to an animal is considered mutilation.

### ***Signs of HI = YES      Final Evaluation = Variable***

If the harvest/mutilation is post-mortem, then the HI did not contribute to the stranding, but the circumstances surrounding the mutilation may have contributed to the stranding event (e.g. fishery). Unless you have information that the animal WAS or WAS NOT affected by human activity prior to mutilation, you cannot accurately provide a Final Evaluation therefore it must be scored as CBD. Evaluation of mutilation cases is problematic since, in most cases, there is very little information about the circumstances surrounding the mutilation. For example; was the porpoise caught in a net and its flukes removed to get it out of the net or did it strand on the beach and a curious passerby removed the flukes for a trophy? In the former case, the mutilation would have been directly related to the stranding event. In the latter case it would not be related. If you don't know what happened, you should score the Final Evaluation as CBD (0).

### ***Harassment/human interference***

Perhaps the most difficult form of human interaction to deal with when it comes to strandings is interference or harassment.

#### ***Definitions***

**Harassment** - Any human activity, intended or not, that causes an animal to change its behavior is considered harassment. Objectively, if the harassment is not observed by the responder, it is difficult to determine if it occurred, and even more difficult to document it. Subjectively, unless an animal is handled by the harassers (e.g. pinniped pup), it is difficult to determine if the harassment caused the stranding event.

If human activity other than that of permitted stranding responders and their designees affected an animal in any way, HI = Yes. This is true even if the animal is dead or dying and, for example, put in a truck or boat to be moved by well-meaning, but un-permitted would-be-rescuers. It is obvious that in these cases, the illegal handling does not cause a stranding but, objectively these cases are no different than post-mortem mutilation and must be scored YES for signs of HI. However, the subjective evaluation and numeric score allow the examiner to take into account the circumstances surrounding the event.

#### ***Evaluating undetermined HI cases***

Although very little on the data sheet is directed toward harassment, it is a very real and prevalent form of HI, especially regarding live pinnipeds. On the data sheet, report a description of the harassment event, including names and contact information of witnesses, in the stranding event section. Indicate image documentation and where any images will be archived. The Final Evaluation determination will depend on the circumstances of the stranding (or whether a stranding even occurred).

**Evidence (w/examples)**

Harp seal (*Phoca groenlandica*) on floating dock where pilings are being driven in MA (right).

Harbor seal weanling (*Phoca vitulina*) in MA being harassed by bystander (see shoes at top of image; below left).

Feeding and swimming with wild cetaceans like this bottlenose dolphin (*Tursiops truncatus*) is illegal in the US and can lead to aggressive behaviors and reduced fitness (below right).

**Unknown or undetermined interactions**

Even with a broad understanding of marine mammal human interactions, some situations are difficult to understand. This protocol will aid in consistently collecting and reporting the data, but it would be impossible to discuss every possible type of interaction. Below is an example of an odd case.

**Evaluating an Undetermined Interaction Case**

Code 3+ bottlenose dolphin with no skin and a cinder block tied to its flukes



This case is similar to a mutilation case. The carcass was found floating rostrum up in a channel in VA. There is a sign of HI with the cinder block tied to the flukes. Perhaps a beach-front homeowner towed the carcass offshore and tied the cinder block on the carcass hoping to keep the already dead animal off his property. Perhaps the animal was caught in fishing gear and the fisher removed it and weighed it down to prevent it from washing ashore. While we cannot tell which of these hypothetical scenarios (or any other for that matter) may have led to the observed HI, we score the Final Evaluation as CBD (0).

***Signs of HI = YES    Final Determination = CBD***

HI is obviously YES, but we have no knowledge of the circumstances of the HI. Final Evaluation= CBD (0)

## **Confounding Variables**

When conducting an HI evaluation, it is important to understand and acknowledge confounding variables. The best pathologist in the world cannot determine if HI is present on a severely decomposed animal. Understanding what can inhibit your exam and what can mimic marks made by human activities is a key part of conducting a thorough examination. This is where experience is helpful. Know what predators and scavengers occur in your region. If you have no other resources, leave a carcass exposed and revisit it repeatedly to see how it decomposes and what marks are left by local wildlife. Confounding variables can include:

- Natural and unknown marks
- Immediate death (exsanguination & asphyxiation)
- Predation
- Scavenger damage (aquatic & terrestrial)
- Decomposition (tissue degradation & bloating)

### ***Natural and unknown marks***

#### ***Cetaceans***

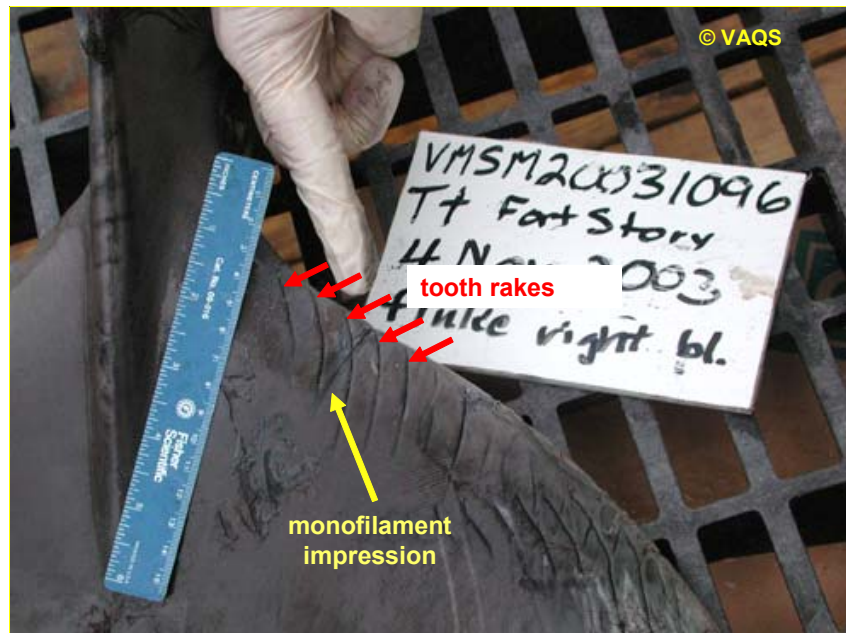
Because cetacean skin is delicate, many animals carry lesions and/or scars from conspecifics (members of their own species), predators or prey. Scars from teeth or 'tooth rakes' are common marks seen on cetaceans. The rakes can be from conspecifics, which is common in the social delphinids, or from predators such as orca or sharks. Deep diving squid eaters such as sperm and beaked whales often have scars and impressions from squid tentacles and scars from cookie cutter sharks. Animals that carry hard barnacles such as humpback whales often have circular scars from barnacle attachment sites.

All of these marks can obscure and confuse HI marks.

Cetacean skin shows impression and lacerations prominently. Unfortunately, almost anything that touches it leaves marks on a cetacean's skin, which can make it difficult to distinguish natural marks from those left by human activities. In addition, after a cetacean dies, the skin degrades quickly both in water where it begins to slough and in air where it desiccates and sun burns. For example; it is important to take note of the conditions under which an animal strands. Knowing that there is an oyster bar offshore of the marsh where a pilot whale stranded can help explain nonparallel linear lacerations on the ventrum.



Dorsal view of the right fluke of a bottlenose dolphin (*Tursiops truncatus*) with both natural marks (tooth rakes-red arrows) and anthropogenic (human-made) marks (monofilament impression- yellow arrow; right).



This bottlenose dolphin has both recent (darker gray) and healed (white) tooth rakes from other bottlenose dolphins. We know the rakes come from other bottlenose dolphins because of the inter-tooth distance. Other species will occasionally rake each other during social interactions. Bottlenose dolphins have been known to bite and rake harbor porpoises during aggressive interactions. In the image above, there was one monofilament impression and several lacerations (difficult to see here but visible in other images) in the same area as the tooth rakes.



Humpback whale (*Megaptera novaeangliae*) flukes (top left-dorsal surface of left fluke; bottom left-ventral surface of right fluke) showing orca rake marks (red circles) and a possible entanglement scar (red arrow).



This stranded humpback whale has healed tooth rake scars (white parallel lines) from killer whale teeth as well as a possible scar from a previous entanglement. Note that the tooth rakes are on the flat surface of the flukes, and the possible entanglement scar wraps around the leading edge of the fluke and continues to the ventral surface.

The flukes of a bottlenose dolphin (*Tursiops truncatus*) with unusual lacerations on the dorsal surface (right).

Wider angle view of the same animal (below). The marks were definitely post-mortem because no marks were visible in photos of this dolphin taken the day before.



Responders had attempted to retrieve the carcass on the previous day but did not have the manpower to lift the animal over a bulkhead. They took pictures and returned the next day. Pictures from the first day do not show these marks. They could have been made by a knife, but it is also possible that a raptor (vulture or eagle) tried to scavenge the carcass. There were no other suspicious marks on the carcass. Not knowing what caused the marks, the responders scored the carcass as CBD.

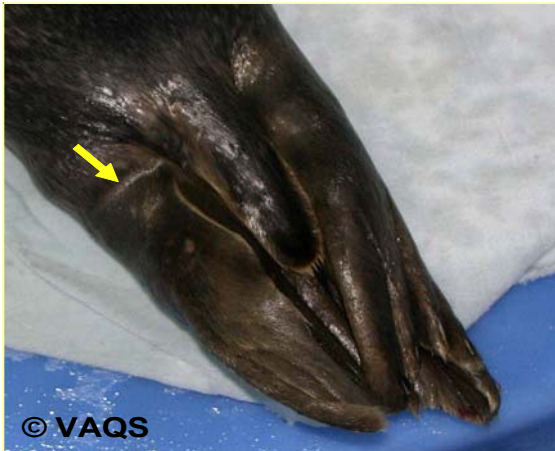A white-sided dolphin (*Lagenorhynchus acutus*; below) stranded in poor external condition (>50% skin missing) with unusual diagonal and 'X-shaped' marks on flank. This case is an example of a degraded animal with unusual marks. This white-sided dolphin had no epidermis on the right side, but it had several thick diagonal marks ~1cm wide and 10cm long. Some of the marks formed an 'X'. There weren't any marks on the leading edges of the dorsal, flippers or flukes. Unable to explain the marks, the responders scored it as CBD for HI.





### Pinnipeds

There are times when it is difficult to determine if a lesion is caused by HI. In these cases, if you are equally unsure whether the marks are natural (due to predation, scavenging or disease), score the lesion as Signs of HI = CBD.

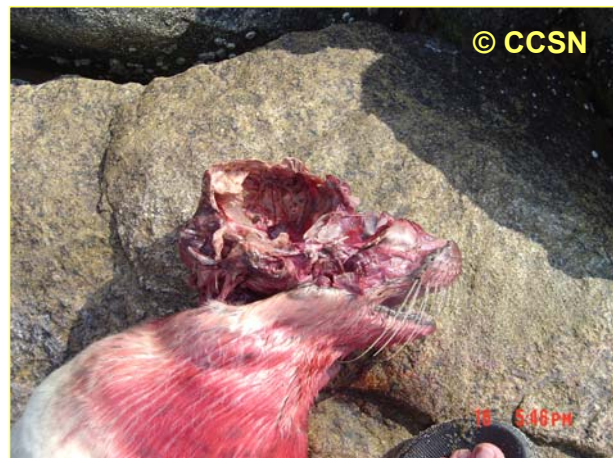

Harbor seal (*Phoca vitulina*) showing circumferential impressions around thorax and abdomen (*above*), and circumferential impression around left rear flipper (*left*).

This live stranded harbor seal was brought to VAQS for rehabilitation. When it arrived, the fur was dry and, due to the animal's condition, it was kept dry for 24 hours. When it was given access to water, the impressions seen in these images became very prominent. They had not been evident when the seal was dry. There were no other external lesions on the animal. Unsure of the source of the lesions, the staff scored the animal as CBD for HI. If they examine animals known to have been entangled and observe similar lesions, they may reassess the diagnosis on this seal.

Harbor seal (*Phoca vitulina*) found on rock jetty with unusual wounds to the head. In this case, the skull was opened and the brain removed (*right*).

This dead harbor seal had an unusual wound to the head. The skull was exposed, opened, and the brain was missing. While it is not rare for coyotes in the area to crush a seal's skull, it is uncommon for the brain to be the only tissue eaten. Likewise, carcasses are occasionally mutilated when humans harvest tissues for sale on the black market. These tissues, however, are usually reproductive tissues, not the brain. The responders were unsure what caused the lesion and scored it as CBD for HI. If, in the future, the source of the lesion is discovered, the diagnosis will be changed accordingly. Note that the rocks surrounding the animal are clean (*right*).





**Immediate death**

Injuries associated with immediate death (peri-mortem) are not uncommon. With peri-mortem injury or underwater entrapment, it can be difficult to evaluate whether the lesions occurred when the animal was alive because there is little or no tissue reaction before the animal dies.



This image (left) shows the ventral surface of the flukes of a stranded right whale (*Eubalaena glacialis*).

The left fluke of this whale was torn off exposing large vessels which likely caused the animal to bleed to death in a very short time. Although, there was no histological support for peri-mortem injury from this wound, a separate head wound deep to the bone showed gross and histologic evidence of hemorrhage, suggesting that this pregnant whale was struck when she was alive and died shortly thereafter.

Interestingly, a naval vessel reported hitting a whale of unknown species seven days prior to the stranding. They reported seeing blood in the water but did not follow the whale. Independently, a recreational fisher reported seeing a whale with half of a fluke bleeding profusely in the same area as the reported vessel strike 45 min later. Subsequent aerial surveys did not locate the injured whale and this whale (probably the same animal) stranded days later approximately 50 miles south of the vessel strike location.

**Predation and scavenger damage**

Predation by sharks and large terrestrial animals is not uncommon and can destroy or mimic evidence of HI.

*Terrestrial predators and scavengers*

Scene from a harp seal (*Phoca groenlandica*) that was preyed on by a coyote (right). Note the bloody trail in the upper left of the image; this is where the coyote dragged the animal up the beach.







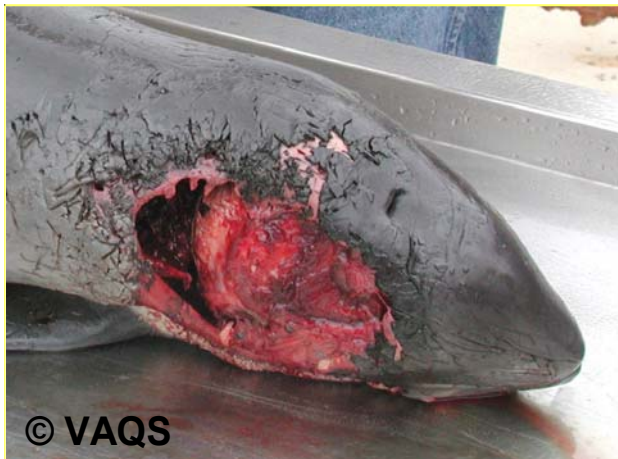Damage done to the carcass after it was killed: the skull is exposed, skin, fat and muscle have been torn from the thorax. Note paw prints in sand surrounding the carcass (*left*).

A view from the back of the carcass shows the obvious drag marks (*below left*).



Coyotes in the northeast, polar bears in Alaska, and other large, terrestrial predators will attack live animals stranded or hauled out on beaches. In the series above, the harp seal carcass has been dragged (see bloody trail in top right and left images). There are coyote footprints in the sand and no human prints. This pattern of wounds is characteristic of coyote predation in Cape Cod, MA. Note how cleanly the pelt has been removed from the carcass. Without the circumstantial evidence related to predation and previous experience with coyote predation, a naive responder might think the pelt was removed with an instrument.

Harbor porpoise (*Phocoena phocoena*) ventral view showing typical bird pecks from gulls (*right*).



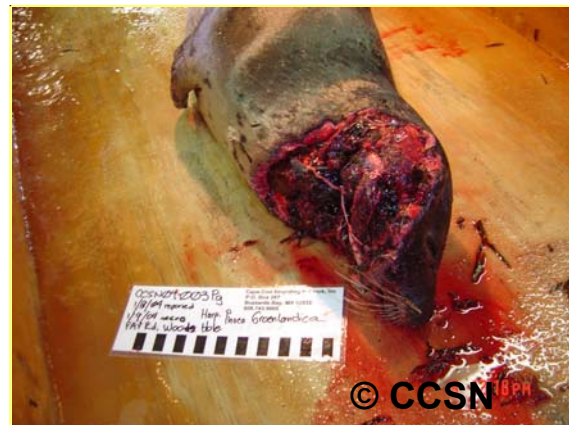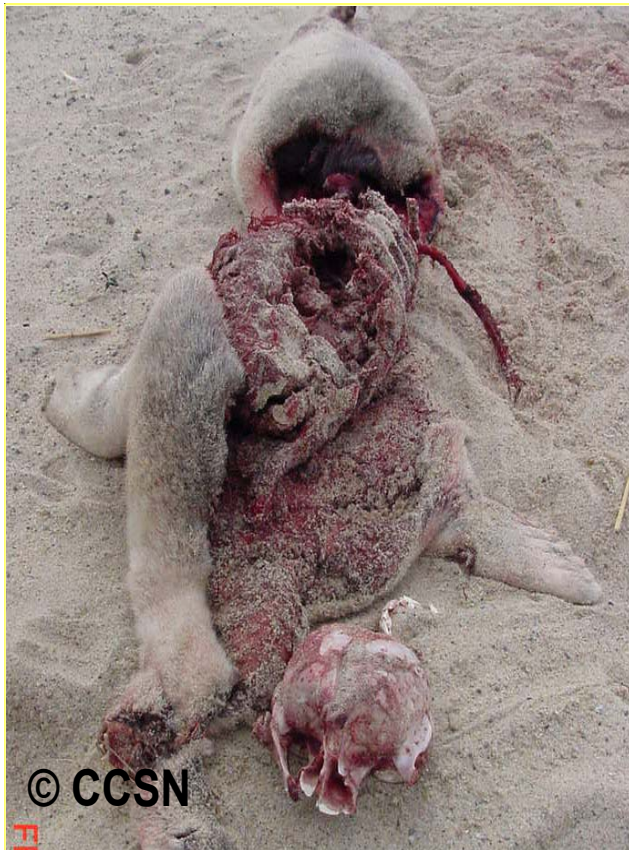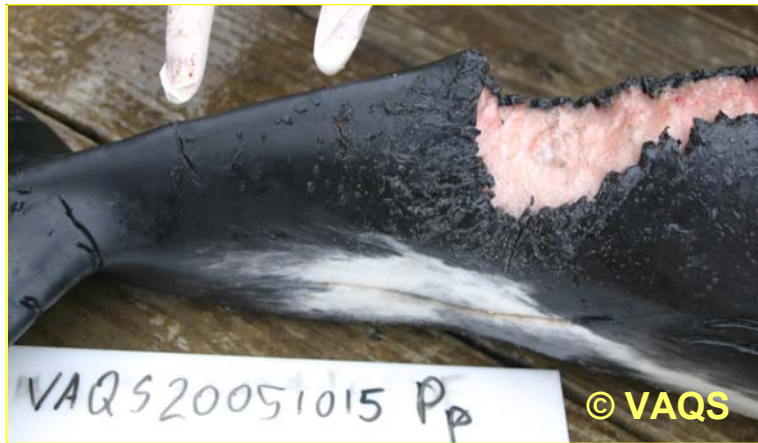Harbor porpoise (*Phocoena phocoena*) scavenged by birds, most likely black backed gulls, who tend to target the jaw fat (*left*). This type of a lesion is typical of bird scavenging but is often mistaken by unexperienced observers as a shotgun lesion.



Harbor porpoise (*Phocoena phocoena*) dorsal peduncle scavenged by foxes and birds (right).

Harbor seal (*Phoca vitulina*) from Cape Cod, Massachusetts scavenged by coyote (below left).

Harbor seal (*Phoca vitulina*) with coyote damage on head (below right).



Carcasses, and, sometimes live animals, stranded on beaches are exposed to scavengers and predators of all types. Two of the most destructive scavengers are birds (gulls, vultures, some raptors) and mammals (coyotes, foxes, raccoons and others). Often animals have been scavenged by a host of critters. Scavenging by gulls, sharks, and other animals can mask evidence of HI or mimic HI lesions.

Learning to recognize evidence of scavenger and predation damage common in your area is important. Comparing exposed tissue to that which was buried or submerged can help determine what marks may have been caused by scavengers and predators and what may have been present before stranding (such as HI lesions).

- Birds target the eyes and mandible (lower jaw) in order to get into the body cavity
- Coyotes will partially skin a seal to expose muscle and fat
- Coyotes target the rear flanks, head and throat if attacking a live animal (bite wounds are similar to HI lesions such as gaff wounds (look for number of wounds and patterns, a gaff would rarely be used on the head)
- Foxes and raccoons will chew on the distal edges of fins and flippers

If an area is undisturbed when you approach the carcass look for tracks in the substrate. Birds and mammals leave distinct tracks.



### Marine predators and scavengers

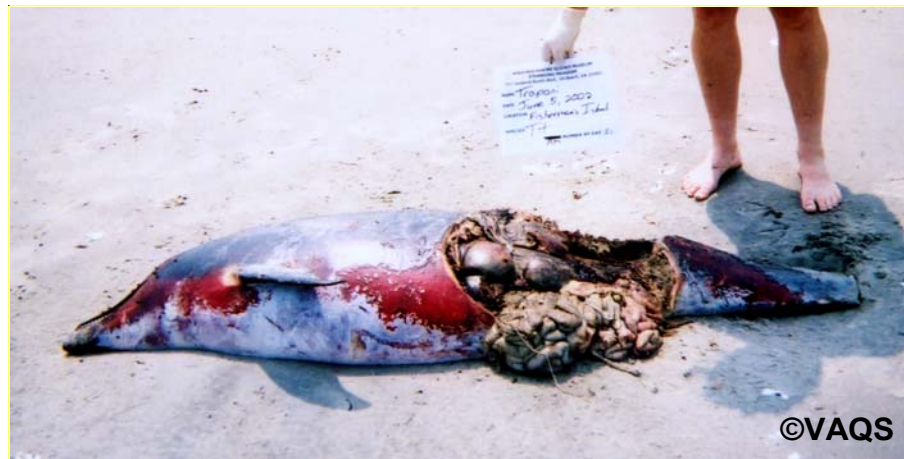Shark attacks on live animals and scavenging of dead animals are both common occurrences. It can be challenging to determine whether shark damage was pre or post-mortem, so we group both together as predation and scavenging. Other marine scavengers (amphipods, crabs, etc.) tend to leave marks similar to terrestrial scavengers.

While there are other marine scavengers, sharks pose the most significant hindrance to evaluation of animals for HI because of the size of the wounds they create. The location of shark lesions can be indicative of whether lesions were pre- or post-mortem. When attacking live prey, sharks will target the genital area, approaching from below and behind their prey. When scavenging dead animal, sharks will target any exposed area and may concentrate on wounds and lesions. For example, bloated carcasses generally float belly-up, resulting in shark bites on the dorsal surface. An area that has a lesion, especially if there are open wounds, is often the target of attack. Look carefully around bite wounds for evidence of other underlying lesions (especially propeller slices).

Bottlenose dolphin (*Tursiops truncatus*) stranded in Virginia with a large shark bite and missing flukes (right).

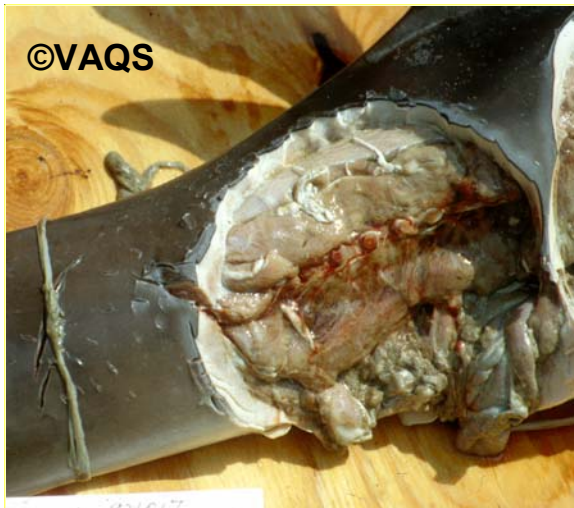Bottlenose dolphin (*Tursiops truncatus*) with shark bites, ventral orientation of the bites could indicate pre-mortem attack (below).

Decomposed bottlenose dolphin (*Tursiops truncatus*) from Virginia with numerous unknown



marks and a semicircular series of lesions indicative of a shark 'taste' (above).

Neonate or still born bottlenose dolphin (*Tursiops truncatus*) with shark bite (left).



Learn to recognize shark 'tastes' (tooth marks without a bite) and tooth rakes and distinguish them from line marks. Note the peduncle of the dolphin (top image-previous page). It was severed cleanly in a straight line. Compare the geometry of the large bite wound to the peduncle which has a distinct curve. It is unlikely that a shark would sever the flukes. This carcass was scored as YES for appendages removed because the lesion was indicative of the flukes being cut off instead of bitten off.

### Decomposition

When encountering a degraded carcass, there is very little you can do to salvage all but the most obvious HI lesions. If a carcass is sunburned on one side, it may be relatively intact on the other. Protecting the 'good' side from the sun until examination can help. These carcasses should rarely receive a score of NO for Signs of HI because it is unlikely that anyone could detect HI lesions in the face of decomposition. When carcasses such as these have clear signs of HI it is often challenging to make a subjective determination of anything other than 0(CBD).

### Cetaceans

Cetaceans degrade very quickly externally when skin is exposed to sun, wind and heat. When floating or submerged for days, the carcass loses its epidermis revealing the white blubber or hypodermis. Peeling, sloughing and/or sunburned skin obscures marks, as does freezing and desiccation. As animals decompose, appendages degrade, the body cavity opens and evaluation becomes difficult. If you cannot examine a carcass immediately, cover it with a wet towel and put it in the shade. If you must freeze a carcass before examining, place in a tightly wrapped plastic bag.



Decomposed (code 4) harbor porpoise (*Phocoena phocoena*) missing head, appendages and most of the skin (above).



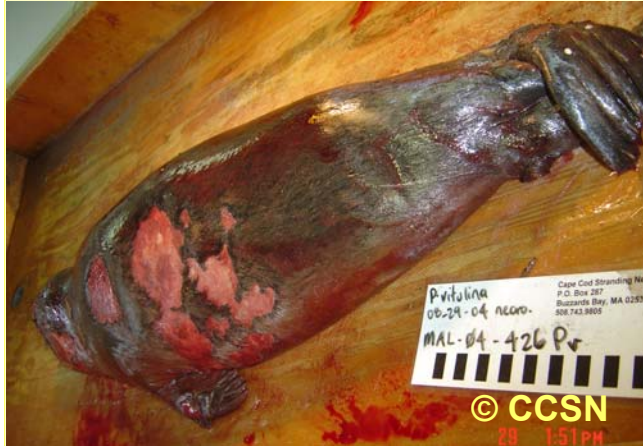Decomposed (late code 3) bottlenose dolphin (*Tursiops truncatus*) with desiccated and peeling skin and rendering blubber (left).



### Pinnipeds

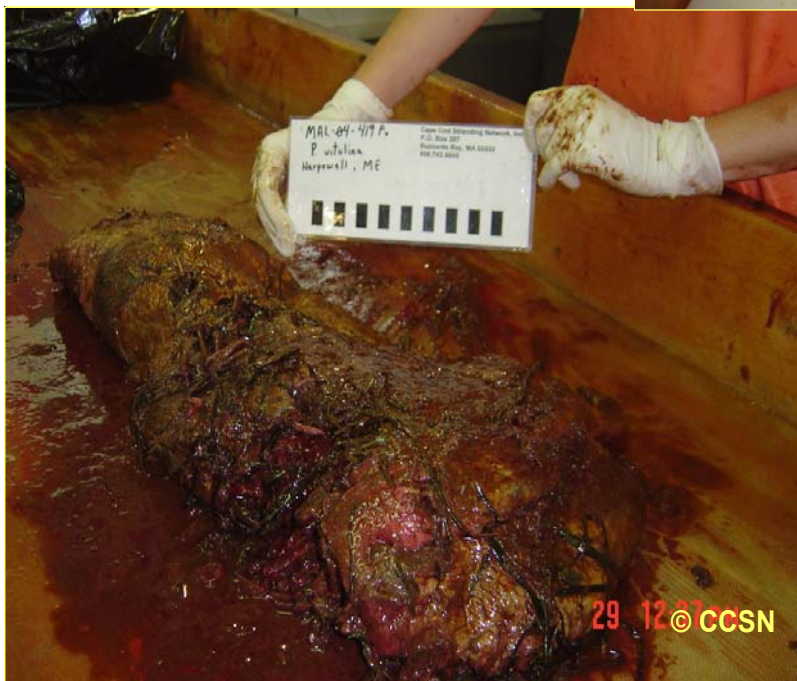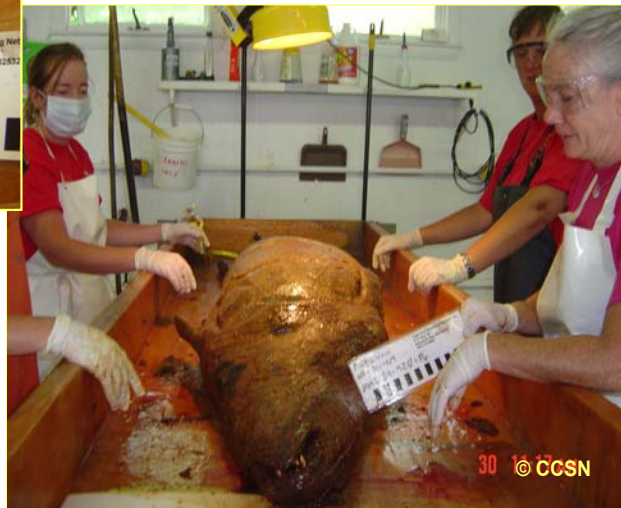This was a set of pinniped carcasses that were degraded upon collection, frozen, then thawed. If at all possible, carcasses that are to be frozen should receive an external HI exam BEFORE FREEZING. Even when carcasses are wrapped tightly in plastic, freezing causes desiccation (drying out), creates marks, and can cause cracking in the skin.

The carcass below was recovered after floating. The side of the carcass that was exposed to the sun was burned and desiccated and the side exposed to the water had sloughed all skin (and fur) and appeared stringy. When a carcass pours out of a bag (see *bottom left*) there is very little you can do in the form of an HI exam (or any exam for that matter). With any type of HI, decomposition obscures lesions and causes carcasses to bloat, then deflate, making evaluation difficult.



Decomposed (late code 3) harbor seal (*Phoca vitulina*) that had been recovered after floating, was frozen and then thawed (left).

Ventral view of a badly decomposed (late code 3) harbor seal (*Phoca vitulina*) that had been frozen and thawed (right).



Front view of a badly decomposed (code 4) harbor seal (*Phoca vitulina*) that had been frozen and thawed (left).



## Evaluating a Decomposed Carcass



Left oblique view of a code 3 white-sided dolphin (*Lagenorhynchus acutus*) showing degradation of the skin (*above*). Note the peeling skin on the dorsal thorax and condition of the dorsal fin. This is an example of the other end of the code 3 spectrum from the first case study.

**EXTERNAL EXAM:** Although there was some bloating, we felt that we could confidently say the carcass was not emaciated because of the fully rounded epaxial musculature. As seen from the image, there was a considerable amount of skin loss, especially on the right side. The dorsal fin and flippers were degraded and/or scavenged. Since they were present, although degraded, we scored the appendages as NO for mutilation (appendages removed).

Despite it's condition, the body was intact and was scored as NO for body sliced. There was no gear or debris on the body. It was difficult to assess the body for other pathologies and HI lesions so we scored CBD in both of these fields.

**INTERNAL EXAM:** There were whole squid & whole fish in the fore-stomach. Both lungs were fluid filled, heavy & sopping. There was no other obvious pathology.

**HISTORY:** This was one of many offshore delphinids that stranded in the area in spring of 2004 during a UME. Most carcasses were decomposed. Those that had stomachs had recently eaten squid. HI was suspected, but no evidence was obtained.

## Signs of HI = CBD

It is always difficult to admit defeat, but there are times when even the most experienced responder cannot determine if signs of HI were present. In our gut we may 'know' that something anthropogenic was involved, but we must remain objective.

Although you may not be able to objectively say there were signs of HI, if you feel that there was something other than natural death involved, it never hurts to write down your thoughts in a necropsy report or on the HI form. You may revisit the case in the future with new knowledge. Despite several observations consistent with fishery interaction (full stomach, robust body condition, fluid in lungs) there were no definitive HI marks.

## Necropsy and Sampling

### *The importance of an internal exam*

Most stranding response organizations have a system for examining those animals that die or are humanely euthanized. A Human Interaction Evaluation on a carcass is not complete until a full necropsy has been conducted. (Obviously, this is not the case for live stranded animals.) The internal examination is an important part of the overall process because it can provide insights into the overall health of the individual and may also yield further evidence of human interaction. The data sheet guides the examiner to note particular internal findings that are often consistent with human interaction. For example, debris or gear found in the gastrointestinal tract is a form of HI (debris/gear ingestion). Froth in the lungs and bronchi is indicative of agonal death and may help support or refute external findings. Bruising and subdermal hemorrhage may reveal blunt trauma that was not evident externally. These are just a few examples of the many types of evidence that may be found internally. Thus, whenever possible, a full internal exam (necropsy) should be done.





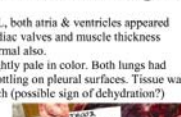


### *Standardized protocol*

As with the external exam, it is important to develop a standard routine when conducting a necropsy. Taking apart the animal and sampling it in the same order each time will help to minimize mistakes.

Although we do not provide a necropsy protocol as part of the human interaction evaluation protocol, the HI data sheet does prompt the examiner to describe key internal elements that may show signs of HI. Be sure to reference your necropsy report in the comments section of the HI data sheet.

### *Necropsy report*

The necropsy report form is an important part of the documentation process. Most institutions have developed their own datasheet to meet their needs (example at right). Many institutions will readily share their form for use by other stranding responders. If you do not currently have a necropsy form, contact other networks for examples and either adopt one of the forms for your institution, or craft an original to best suit your needs. A good Necropsy Report Form should capture basic data such as field number, stranding location,

VAQS Draft Necropsy Report Do Not Cite or Use Without Permission	
 <b>Necropsy Examination Report</b>	
<b>Field Number:</b> CTH002 <b>Species:</b> <i>Grampus griseus</i> <b>Strand Date:</b> 26 Sept 2005 <b>Necropsy Date:</b> 26-27 Sept 2005 <b>Strand Location:</b> Carova, NC <b>Length:</b> 224.6 cm <b>NOAA SER called:</b> ( Y )	<b>Latitude/ Longitude:</b> 36.40764 °N 75.83165 °W <b>Condition:</b> 1 <b>Sex:</b> Male <b>Weight:</b> 115.8 kg <b>Good Dorsal Fin:</b> ( Y )
<b>Associated Data Sheets:</b> Marine Mammal Stranding <input checked="" type="checkbox"/> Morphometrics <input checked="" type="checkbox"/> Human Interaction <input checked="" type="checkbox"/>	
<b>Samples Taken:</b> blood drawn <input checked="" type="checkbox"/> <b>Frozen:</b> Skeleton <input type="checkbox"/> Teeth <input checked="" type="checkbox"/> lung/brain (for methylation) <input checked="" type="checkbox"/>	
<b>10% NBF:</b> full histo suite <input checked="" type="checkbox"/> partial histo: (not marked/boxed) <input checked="" type="checkbox"/>	
<b>ETOH:</b> <b>DMSO:</b> <b>Samples sent:</b> brain sampled & all sent to Dave Rotstein @ UT	
<b>VAQS Draft Necropsy Report Do Not Cite or Use Without Permission</b> <b>NECROPSY OBSERVATIONS</b>	
<b>External Exam/Condition:</b> Animal appeared underweight, but no visible signs of starvation. Minimal amount of both conspecific and non-conspecific delphinid rake marks were noted, mainly on thorax and tail stock. Animal also had odd skin lesion on leading edge of left pectoral flipper (possible old healed bite mark). <div style="display: flex; justify-content: space-around;">   </div>	
<b>INTERNAL EXAM</b> <b>Blubber:</b> Blubber appeared to be normal in color but blubber thickness seemed to be thin, (0.7cm - 1.2cm spanning from lateral midline of axillary to dorsal fin to peduncle) <b>Muscle/Skeletal:</b> NSF, no broken or fractured bones <b>Lymph Nodes:</b> NVL, (pre-scap, lung, and mesenteric lymph sampled) <b>CNS:</b> NVL, (brain sampled whole and cerebral-spinal fluid taken for Dave R. @ UTenn) <div style="display: flex; justify-content: space-around;">   </div>	
<b>Heart:</b> NVL, both atria & ventricles appeared normal. Cardiac valves and muscle thickness appeared normal also. <b>Lungs:</b> Slightly pale in color. Both lungs had moderate mottling on pleural surfaces. Tissue was tacky to touch (possible sign of dehydration?) <div style="display: flex; justify-content: space-around;">   </div>	
<b>GI Tract:</b> Fore stomach completely empty. Brown colored fluid approx. 100ml. in pyloric stomach. Small amount of fluorescent green feces was noted and sampled <b>Liver:</b> NVL, tissue was brick red/brown in color and organ had crisp margins <b>Kidney/Bladder:</b> NVL, (approx. 3cc of urine sampled for biotoxology) <b>Reproductive Tract:</b> NSF, gonads sampled <b>Parasites:</b> NSF	
3 Field Number: CTH002	

date of stranding, date of necropsy, storage prior to necropsy, and the names of the prosectors. A brief stranding history should be included, as well as a summary external exam. The internal exam is often recorded by organ system or individual organ. Examiners should provide as much information as possible regarding their gross observations. Note the internal condition of the animal, including the appearance of the organs, coloration, texture, size, and any abnormalities. Also describe in detail any lesions, tumors, abscesses, subdermal bruising/hemorrhage, *etc.* The gross findings reported on the necropsy form should be submitted with any samples disseminated for analyses, especially histopathology. Your notes will provide the analysts with information that may provide critical insights into their microscopic observations, increasing their ability to accurately interpret their findings.

### ***Suggested sampling***

In addition to recording your gross observations, sample collection is an important element in the Human Interaction Evaluation process. The confirmation of the *SUBJECTIVE* evaluation may lie in the analysis of HI samples. Determining whether an injury occurred pre-, post-, or peri-mortem will aid in confirming your final diagnosis. In addition to collecting standard samples (genetics, life history, contaminants, histopathology, biotoxicology, virology, microbiology, *etc.*), be sure to sample wounds or other evidence of human interaction. Whenever possible, HI lesions should be sampled for histopathology. These samples should be taken in the same manner any wound or lesion would be sampled for histopathology. Be sure to capture normal tissue on either side of the lesion, and sample past the full depth of the lesion (if possible).

## **Outreach and Education**

### ***The role of public sentiment in conservation and management***

Marine mammals tend to generate a great deal of public interest. Stranding events are often the only time that members of the general public get to see these “charismatic mega fauna” up close and personal. Emotions can run high at stranding events, with bystanders wishing to help in the efforts to rescue live stranded animals or investigate the deaths of animals that do not survive. Often, there is a rush to find a cause and to lay blame for a death, and different forms of human interaction may come to mind. Bystanders witnessing a mass stranding of dolphins may begin to ask if military actions or ocean noise caused the stranding. Others may suggest pollution as a culprit, or fisheries interactions. The reality is that human interactions can pose a difficult dilemma when dealing with the public. Strandings represent a wonderful opportunity to educate the public about marine mammals and the need for sound management and conservation to protect these species. However, it is unwise to cast blame while investigating a stranding. Oftentimes at a stranding, the most accurate answer to such inquiries is, “it is under investigation.” Take care in speaking with bystanders and remember that a thorough exam is necessary before any conclusions can be made, including diagnostics (live animals) and a full necropsy and sample analysis (dead animals).

### ***Being sensitive to other resource users***

Resource use conflicts abound in the realm of natural resource management. Although many of the interactions observed may be due to fishery interactions or vessel interactions, it is important to remember the best likelihood of resolving these conflicts is through cooperative efforts. Alienating fishers will not help to reduce entanglements. Think very carefully before you publicly implicate an industry or group. If you want cooperation in trying to solve a problem with HI, the worst way to go about it is to publicly accuse an individual or group, especially if you have not yet conducted a thorough exam. Furthermore, stranding responders often rely on fishers and other marine resource users to report strandings and aid in response (providing access to injured or deceased animals offshore, *etc.*). Take care not to alienate these groups.



## **Appendices**

Appendix I: Data sheet for evaluating stranded marine mammals for signs of human interaction (2 pages).

Appendix II: Detailed instructions for human interaction data sheet (7 pages).

# **PROTOCOL FOR EXAMINING MARINE MAMMALS FOR SIGNS OF HUMAN INTERACTION**

## **Exam Information** *(fill in or circle most appropriate)*

1 Field #: \_\_\_\_\_ Species: \_\_\_\_\_

2 Examiner: \_\_\_\_\_ Recorder: \_\_\_\_\_

3 Date of exam: \_\_\_\_\_ Condition code (at exam): 1 2 3 4 5 CBD

4 Preservation: alive fresh frozen frozen/thawed Body condition: emaciated not emaciated CBD

5 Documentation: digital print slide video Image disposition: \_\_\_\_\_

6 Integument: normal abnormal decomp/scaven % Skin missing: <10% 10-25% 25-50% >50%

7 Explanation of terms:  
 YES = I have examined the area and found signs of human interaction  
 NO = I have examined the area did not find signs of human interaction  
 CBD = I have examined the area and could not determine whether there were signs of human interaction (i.e. the part was missing, degraded, or signs were ambiguous)  
 NE = I did not examine the area  
 NA = this animal doesn't normally have that part (i.e. seals have no dorsal, dolphins have no rear flippers)

	WHOLE BODY EXAM	YES	NO	CBD	NE	NA	Image taken (Y or N)
8	Appendages removed / Mutilation <i>(with instrument)</i>						
9	Pelt removed / Mutilation <i>(with instrument)</i>						
10	Body sliced / Mutilation <i>(with instrument)</i>						
11	Gear/debris present on animal <i>(includes tags)</i>						
12	Gear retained <i>(name &amp; contact info in Comments)</i>						
13	External pathology <i>(pox, tattoo lesion, abscess, other)</i>						
14	Natural markings <i>(scars, tooth rakes, unusual pigmentation)</i>						
15	HI lesions <i>(fishery, gaff, gunshot, propeller, healed HI scar, brand)</i>						

16 Predation/scavenger damage *(circle all anatomical areas where damage hinders evaluation; numbers coincide with anatomical areas below)*: 17 18 19 20 21 22 23 24 25 26 27 28 29 30 NONE

										Origin of Lesion										
										Type of Lesion				Gear				Other		
DETAILED EXAM OF ANATOMICAL AREAS		YES	NO	CBD	NE or NA	impression / laceration	penetrating wound	healed HI scar	abrasion	other / CBD	twine / line	net	other / CBD	monofilament	multifilament	CBD	propeller	gunshot	other / CBD	image taken?
17	rostrum/snout/palate																			
18	mandible/tongue																			
19	head																			
20	R front appendage																			
21	R body																			
22	dorsum/dorsal fin																			
23	L front appendage																			
24	L Body																			
25	ventrum																			
26	peduncle																			
27	R rear appendage																			
28	L rear appendage																			
29	flukes/tail																			
30																				

Field #: \_\_\_\_\_

	INTERNAL EXAM Date of exam:	YES	NO	Partial	CBD	Image taken	Detailed Info (circle all that apply)
31	Internal exam conducted						Details in Comments section -use line number
32	Bruising/blunt trauma						Details in Comments section -use line number
33	Skeleton examined						Details in Comments section -use line number
34	Broken bones present						Associated tissue reaction: YES NO CBD
35	GI tract examined (circle contents)						intact prey partially digested hard parts only debris/gear empty other
36	Lungs/bronchi examined						Details in Comments section -use line number
37	Lung/bronchi contents						froth fluid air ( color: )
38	Other pathologies noted						Details in Comments section -use line number

39 **Comments** (note line number from left margin before each comment):

40 **Signs of Human Interaction Observed:** YES NO CBD (transfer to Level A Datasheet)

41 **Stranding Event History/Circumstances:**

42 **FINAL HUMAN INTERACTION EVALUATION:** If you circled YES above (#40), evaluate the external exam, necropsy, carcass condition and circumstances surrounding the stranding event to answer the question below.

**How likely is it that the documented human interaction contributed to the stranding?**

0: Uncertain (CBD)

1: Improbable

2: Suspect

3: Probable

43 **Justification:**





## PROTOCOL FOR EVALUATING MARINE MAMMALS FOR SIGNS OF HUMAN INTERACTION



### Introduction

Evaluating marine mammals for signs of human interaction requires consistent, objective examination by trained personnel. This document is meant to accompany formal training by experienced stranding network participants. This new protocol is divided into an objective data collection section and a more subjective final diagnosis. The primary goal of this protocol is to determine whether evidence of human interaction is present on the animal. The secondary, and more difficult, goal is to determine whether human activities contributed to the stranding event. A positive score for signs of human interaction results from an objective evaluation of an animal or carcass. This evaluation does not attempt to determine whether the signs of human interaction occurred before, during or after a stranding event and does not attempt to qualify the severity of the interaction.

The final, subjective human interaction evaluation takes into account the circumstances of the stranding event and the animal's physical condition. A high score indicates that human activities most likely caused the stranding. A low score indicates that although signs of human interaction are present, the likelihood that the interaction caused the stranding is very low. For example, old, healed, propeller scars on a known whale are unlikely to have caused a stranding during a domoic acid event and a dead dolphin calf covered by debris on a beach following a hurricane is unlikely to have died due to entanglement.

Determining the cause of death is not an objective of this protocol. Without further evaluation such as histopathology and review by veterinarians, pathologists and/or other experts, the exact reason for stranding and cause of death cannot be accurately determined.

Human interaction (HI) data illustrate where problems between marine mammals and humans occur. When collected carefully and consistently, these data can be used to describe the types of interaction taking place (e.g. monofilament net, multifilament net, small or large vessel interaction, ingestion of debris, etc.), thus providing a sound scientific basis for policy and management decisions. The nature of strandings makes it inadvisable to use human interaction data to estimate mortality or changes in the mortality rate due to human interaction.

### Definitions

In order to effectively evaluate marine mammals for signs of human interaction, you must understand what you are looking for. Below are terms and explanations of data sheet sections:

For most of the sections, you must choose among the following answers:

- YES you have examined the area (*i.e.* left front appendage, or snout) and you found signs of human interaction
- NO you have examined the area (*i.e.* left front appendage, or snout) and you found NO signs of human interaction
- CBD (Could not Be Determined) which means either: (1) you have examined the area and could not determine whether the marks you saw were signs of human interaction, (2) you could not properly examine the area because it was degraded (scavenged, skin/pelt missing, mangled, etc.), or (3) you could not examine the area because it was missing (removed, decomposed)
- NE you did not examine the area (an explanation as to why is often helpful – e.g. it was too dark; the animal was too large to roll over, etc.)
- NA this question is not applicable to this animal (e.g. it is a seal and doesn't have a dorsal fin, or it is a dolphin and doesn't have rear appendages)

*Strategy for filling out the human interaction data sheet*

Each new line on the data sheet is numbered in the left hand margin. These numbers serve two purposes: (1) each number corresponds to a section within these instructions with details about how to fill in that line; (2) the line numbers should be entered in the comments section on the second page of the data sheet to indicate to which item the comment refers.

**Page 1:**

**EXAM INFORMATION:** Fill in or circle the most appropriate answer for each of the fields.

- 1 Field #: unique identifying number originally assigned to the animal by response personnel. Note: the field number NEVER changes. If other filing numbers are added or accession numbers from other institutions are added, they should be noted as “additional identifiers”.  
Species: note the genus and species, or common name of the animal.
- 2 Examiner: the person evaluating the animal.  
Recorder: the person recording the information on the data sheet.
- 3 Date of exam: the date that you are conducting the human interaction evaluation.  
Condition Code (at exam): the condition code of the animal at the time of the human interaction evaluation. Use Smithsonian Institution condition codes (Geraci and Lounsbury, 1993).
- 4 Preservation: circle one of following - ALIVE, FRESH (not previously frozen), FROZEN (completely or partially frozen while exam was conducted), or FROZEN/THAWED (previously frozen, but completely thawed before exam).  
Body condition: circle one of following - EMACIATED (clearly thin, concave epaxial muscle, obvious neck, ribs, scapulae, hip bones, and/or vertebral processes), NOT EMACIATED (robust or slightly thin, but not fitting the description of emaciated above) or CBD could not be determined (bloated, decomposed, not examined, etc.).
- 5 Documentation: circle all forms of photo/video documentation that apply.  
Image disposition: indicate which camera, disk, tape, etc. that images were taken or stored on and the acronym of the organization that is maintaining them.
- 6 Integument: (skin, fur, hide) circle one of following - NORMAL (as if it were healthy and alive), ABNORMAL (conditions not associated with decomposition such as: alopecia, skin lesions, sloughing, abrasions, etc.) or DECOMPOSED/SCAVENGED (post-mortem changes such as peeling, sunburn, or scavenger damage).  
% Skin missing: Circle the most appropriate number. Note that this does not apply to alopecia (fur loss) but to SKIN loss.
- 7 Explanation of terms: definitions of common terms used throughout the data sheet.

**WHOLE BODY EXAM:** Before beginning a detailed exam, take a look at the whole animal. If possible, look at all angles and surfaces. Following your whole animal exam, check the most appropriate choice for each category. If you check YES or CBD, describe what you see in the *Comments* section on the next page, noting the appropriate line number. Indicate whether you collected an image of an area with a Y (Yes) or N (No) in the *Image taken* section. If you are unable to examine any areas, note the details in the *Comments* section.

- 8 Head/appendages removed (with instrument, mutilation): Check YES if the head or other appendages (limbs, dorsal fin, fluke, etc.) appear to have been removed from the animal with an instrument (e.g. if there are obvious straight line cuts or straight nicks to the bone), consistent with mutilation. Check NO if all appendages are intact. Check CBD if you are unsure why an appendage is missing or if you cannot examine all appendages. If an appendage was completely removed by scavenging or predation (e.g. shark bite removed entire dorsal fin) you should check CBD.
- 9 Pelt removed (with instrument): – Check YES if the pelt appears to have been removed with an instrument (knife, scraper). Check NO if the pelt is intact (even if the animal's skin is intact but the hair/fur is missing). Check CBD if you are unsure (due to decomposition, etc.) of whether the animal's pelt was removed. Check NA if the animal has no pelt (cetacean or manatee).

- 10 Body sliced (with instrument, mutilation) – Check YES if the carcass appears to be sliced with one or more cuts (from a knife or other blade), consistent with mutilation. Multiple parallel cuts are often indicative of propeller wounds and should be noted under the *HI Lesions* category. Check NO if the body is intact or open body cavity is obviously due to natural causes (e.g. scavenging, predation). Check CBD if the body cavity has been penetrated and you are unsure of the cause.
- 11 Gear/debris present on animal– check YES if the animal is entangled in gear (net, line, pot, buoy, line with hook, etc.) or debris (anything else). Check NO if there is no gear/debris on the animal. Check CBD if you are unsure for any reason (e.g. gear/debris is found on, but not around the animal, or gear/debris was reported on the animal but apparently removed before you responded). Note *gear/debris present on animal* = YES if tags are present on the animal.
- 12 Gear retained – Check YES if the gear was retained by a stranding network or NOAA enforcement official. Note the name and contact information if the gear was retained by anyone other than your organization. Check NO if the gear was not retained. Check NA if there was no gear/debris present on the animal.
- 13 External pathology – If the animal has any lesions that appear to be disease-related such as pox lesions, tattoo lesions, abscesses, or other unexplained lumps, bumps or sores, check YES. Check NO if the animal has no disease-related lesions. Check CBD if you observe lesions and are unsure of their origin or if the integument is too degraded to assess.
- 14 Natural marking – If the animal has any natural markings (e.g. tooth rakes, unusual pigmentation, any non-HI scars) check YES. If the natural marks hamper your examination please note in the COMMENTS section. If there are no natural markings, check NO. If you cannot tell if there are any marks or are unsure of the origin of marks/scars check CBD.
- 15 HI lesions – Note lesions that may be associated with human interaction (fresh or healed entanglement or propeller scars, gaff marks, gunshot, healed HI scars, brands, etc.). Check YES if any human interaction lesions are observed. Check NO if no other lesions are observed. Check CBD if you observe lesions and are unsure of their origin or if the integument is too degraded to assess. A detailed exam of these lesions will occur in the next section.
- 16 Predation/scavenger damage – If there is evidence of predation or scavenger damage, circle the number(s) that correspond to the anatomical areas where evidence is seen. If the area affected is not numbered, circle #30, and note the area in the table below (e.g. genital slit, umbilicus, tongue) and note details of the damage in *Comments*.

**17-29 DETAILED EXAM OF ANATOMICAL AREAS**– Examine the animal carefully starting at the head and working caudally down the right, then left, side, finishing with the tail or flukes. For this section, indicate whether you observe any SIGNS OF HUMAN INTERACTION in each *anatomical area* by checking the YES, NO or CBD column. If you were not able to examine an area, check NE, if it does not apply to your animal, check NA. Be consistent; examine anatomical areas in the same order each time you do an exam.

**TYPE OF LESION**- If you checked YES or CBD in any area, proceed to the Type of Lesion section and check all columns that apply.

- An *impression* occurs when a line or net leaves an indentation but does not lacerate or abrade the skin/pelt. Impressions left by net or line usually wrap around the leading and/or trailing edges of a fin, flipper or fluke. Impressions on the leading edge of an appendage may line up with a similar mark on the trailing edge.
- A *laceration* occurs when the skin/pelt is cut. Net and line usually leave linear lacerations. These lacerations may be evenly spaced along an appendage (indicating net) and may be accompanied by impressions.
- A *penetrating wound* occurs when a foreign object punctures or deeply penetrates the body, generally characterized by a small external wound and a wound tract that extends deep into the tissue and often into the body cavity. Sources of penetrating wounds include gaff, knife stab, spear, arrow, gunshot (especially bullet), etc.



- A *healed HI scar* is similar to a natural scar in pigmentation, but exhibits similar characteristics to the other types of lesions described here (e.g. linear scars on leading edges of appendages consistent with entanglement, parallel scars consistent with prop strike, etc.). It is as important to note healed HI scars as it is to note recent (unhealed) HI wounds. Evidence of HI, even if healed and not likely associated with the stranding event, should still be scored positive (YES) for HI.
- An *abrasion* occurs when gear or debris rubs an area and scrapes the skin/pelt without forming an obvious laceration. This often occurs with heavy line or twine entanglement or when loose or trailing ends of gear/debris rub (abrade) parts of the body.
- Choose *other / CBD* for any other types of lesions and describe in the comments section.

ORIGIN OF LESION - Once you determine the type of lesion, move to the origin of lesion section and check all that apply.

LINE is made up of many individual strands (multifilament) and is large in diameter. It is used for moorings, tow lines, forms the float and lead line of nets and attaches buoys and anchors.

TWINE is a small diameter line and can be multi- or mono- filament. Twine is constructed of various materials and is combined in different ways:

MONOFILAMENT twine – a single strand of nylon twine that leaves a single, straight, narrow impression or laceration (Figure 1, A).

MULTIFILAMENT – line or twine made up of multiple strands of material that are twisted or braided together and can leave a distinctive impression (a series of parallel, angled lines or ovals, Figure 1, B and C). If heavier twisted or braided line rubs on a body part or becomes tightly wrapped, it can cause an abrasion.

NET – nets can be made of either monofilament or multifilament twine and have various characteristics: twine diameter, square mesh size (knot to knot), and stretch mesh size (diagonal between opposite knots of a mesh with one knot between; Figure 2). Net impressions are often characterized by either a criss-cross pattern or a bunching of impressions with or without knot marks evident where lines intersect.

Based on the descriptions above, indicate the origin of the lesion:

- *Twine/Line* - select TWINE/LINE if the impression, laceration or abrasion is consistent with the descriptions above, but is not indicative of interaction with a net.
- *Net* – select NET if the marks are consistent with the descriptions above. Nets made of monofilament may leave multiple impressions or lacerations, but each lesion is a straight furrow.
- *Other/CBD* select this column if the marks appear consistent with entanglement or interaction with some type of gear, but you cannot determine which type.

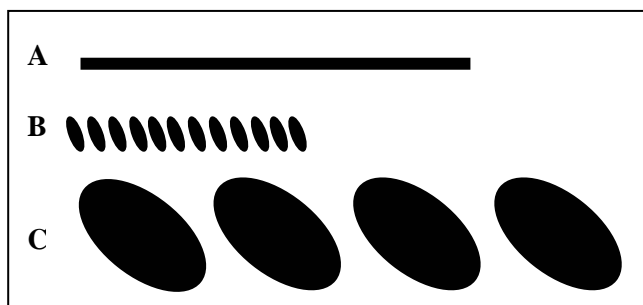


Figure 1: Impressions left by (A) monofilament, (B) twisted twine and (C) twisted line. Impressions are most visible on cetaceans.

If you checked *Twine/Line*, *Net*, or *Other/CBD*, indicate whether lesions were caused by *monofilament* or *multifilament* gear. Select *CBD* if you observe linear marks and you are unsure of the origin.

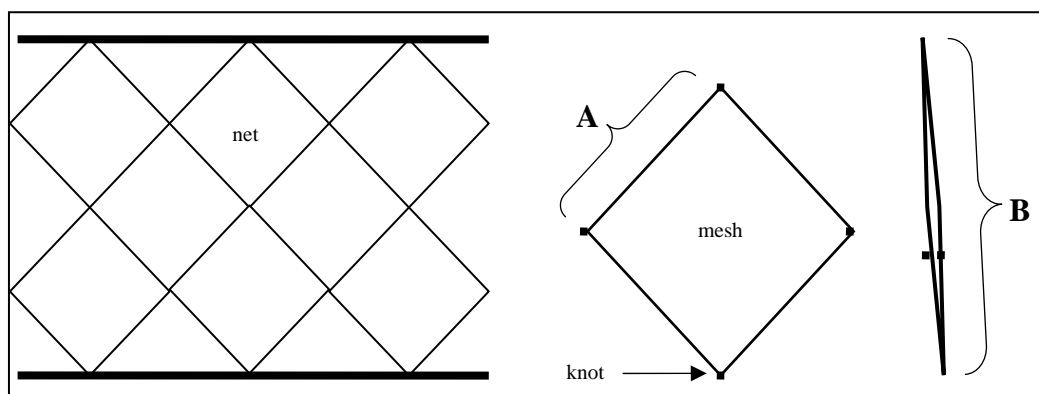


Figure 2: Typical net design. Nets are measured by the depth and length of the meshes hung between the top and bottom lines (float line and lead line on gill nets) and the horizontal length of the meshes. The mesh size can be measured from knot to knot (A) which is called the square or bar mesh size or (B) at it's maximum diagonal width which is called a stretch mesh size. Twine size is the diameter of the twine the makes up the mesh.

If the lesion you noted was not made by gear (line, net/twine), check the appropriate box to indicate the source:

- **Propellers** usually leave deep, roughly parallel lacerations (Figure 3). Lesions can be (A) straight, (B) Z or S-shaped, (C) curved, or open in the middle with thin trails (not illustrated). Large vessels may bisect an animal. Propellers have different sizes, numbers of blades, pitch, and configurations. Vessels can have a single propeller or two propellers separated by varying distances. Two propellers can be mounted on the same shaft rotating in different directions. The latter configuration causes very unusual lesions, unlike those in Figure 3.
- **Gunshot** wounds vary based on the weapon used (shotgun, rifle, hand gun) and the distance from the weapon. Gunshot wounds can be very difficult to identify through gross exam, but can be characterized by single (bullet) or multiple (pellet) puncture/penetrating wounds. Radiographs are often necessary to confirm the findings.
- **Other/CBD**- select this column for lesions with other origins including, gaff, arrow, and debris entanglement, etc. or if you are unsure of the origin of the lesion(s).

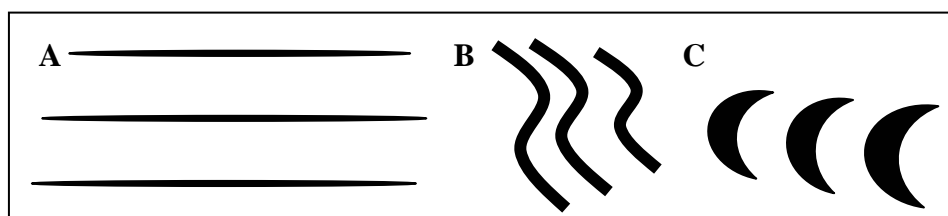


Figure 3: Types of propeller lesions left by different styles and sizes of propeller. The length, depth and spacing between lesions can provide information as to the type of propeller and vessel.

Every area that scores YES or CBD should have an IMAGE TAKEN with identifying information (field number, date of stranding, species, examiner, subject of image, etc.) and a scale (small ruler or something of known size). If film or disk space is not limited, take pictures of all areas. Note Y (yes) or N (no) in the IMAGE TAKEN column.

Every area that scores YES or CBD should have a comment associated with it. Number each COMMENT with the corresponding line number for that anatomical area.

30 If you find lesions in an area not listed in the Detailed Exam table, add the area here and complete the table as explained above.

**Page 2:**

FIELD # - Be sure to fill out the field number on both sides of all pages associated with this animal.

**INTERNAL EXAM** – An evaluation is not complete without a thorough necropsy (internal examination). Some forms of interaction are only evident through internal exam (e.g. ingestion of debris or gear) and a final interpretation may change if an animal with external evidence of HI is found to be suffering from disease, pregnancy complications, injuries, etc. Some observations support a diagnosis of HI (e.g. for fishery interactions-full stomach, froth in lungs) and others provide evidence for HI although nothing was noted externally (e.g. stomach full of man-made debris). Be sure to note the date of the internal exam in the INTERNAL EXAM box.

- 31 Internal examination conducted – If you were able to examine the entire animal, check YES. If you did not examine the animal internally check NO. Check PARTIAL if you examined part of the animal (e.g. abdominal cavity only), then describe in the *Comments* section what was examined.
- 32 Bruising/blunt trauma – indicate if you see any focal area of bruising (discrete area, not diffuse along an entire body region). Note whether the area is associated with an external lesion. If it is not associated with a penetrating lesion or wound, it should be considered blunt trauma. If you check YES or CBD, note the size of the area and the tissue depth (e.g. sub-dermal to blubber, into muscle, through muscle and into mesenteries and organs) in the *Comments* section (do not confuse diffuse post-mortem blood pooling with bruising).
- 33 Skeleton examined – Check YES if the entire skeleton was examined. Check NO if no bones were examined. Check PARTIAL if only some of the skeletal elements were examined. If you check PARTIAL, note in *Comments* section what was examined (e.g. examined skull, head, left ribs and flipper, but not right side or vertebral column).
- 34 Broken bones present - Note whether you observed any broken bones.  
*Associated tissue reaction* -Examine the tissue around the break(s) and circle whether any tissue reaction has occurred (hemorrhage, fibrous tissue, swelling at bone ends, etc.). If you are unsure, check CBD.
- 35 GI tract examined – Check YES if the entire GI tract was examined. Check NO if none of the GI tract was examined. Check PARTIAL if only some elements of the GI tract were examined and note which areas were examined in the *Comments* section (e.g. stomach, but not intestines). Note in the *Detailed Info* column the predominant condition of the contents. Circle *debris/gear* if non-prey items (plastic, line, hooks, etc.) are found. Use the comments section to describe the region of the GI tract (e.g. esophagus, stomach chamber, intestine, or colon) and its contents (e.g. fish, squid, crabs, mussels, milk, plastic bag, unknown). Stranded animals with full stomachs are often suspect cases. Ingestion of gear or debris is considered a human interaction.
- 36 Lungs/bronchi examined - Check YES if both lungs were thoroughly examined. Check NO if the lungs were not examined. Check PARTIAL if you performed a partial examination.
- 37 Lungs/bronchi contents – Circle all that apply in the *Detailed Info* column and describe the contents of each lung, including content volume, in the *Comments* section.
- 38 Other pathologies noted – Note whether any other pathologies were observed, describe in *Comments* section.
- 39 **COMMENTS** – The details of what you observe are required in the section. Provide comments for each item for which you checked YES or CBD. When describing lesions, include measurements (e.g. length, width and depth, distance between lesions), location (e.g. measurement from nearest landmark – 20cm caudal of the right flipper), color, shape and texture. Note the characteristics of the edges (e.g. jagged, straight, rounded) and the direction of linear lesions (e.g. wraps from leading edge of dorsal fin to trailing edge on left side). Number each set of comments using the corresponding line number for that row on the data sheet. Use extra pages if needed and be sure to note the animal's field number in the upper right margin. If this information is provided in the necropsy report or other data sheet, reference that material here.



**40 SIGNS OF HUMAN INTERACTION OBSERVED** – Review your exam notes and circle YES if you observed any signs of human interaction on the animal. Circle NO if you thoroughly examined the animal and did not find any signs of human interaction. Circle CBD if: (1) you did not examine the animal thoroughly, (2) decomposition or scavenger damage hampered the exam, or (3) you are unsure whether marks on the animal were caused by human interaction. This is an objective analysis. It does not take into account the animal's physical condition, the timing of the human interaction with respect to the stranding or the circumstances surrounding the stranding. **TRANSFER THIS INFORMATION TO THE SIGNS OF HUMAN INTERACTION SECTION ON THE LEVEL A DATA SHEET.**

**41 STRANDING EVENT HISTORY/CIRCUMSTANCES** – provide any information about the stranding event or circumstances surrounding the event that would be helpful in determining the HI diagnosis (i.e. fishing, drilling, or other activities, oil spill, unusual mortality events, previous sightings of animal, unusual behavior prior to stranding, etc.). Note any objective details provided by the initial reporter, these may be answers to questions you have asked (i.e. Was there any blood in the water next to the animal? What did it look or smell like when you first observed it? How was the animal positioned (belly up, on its side) when you first observed it?).

If harassment is suspected, objectively describe events in this section including names and contact numbers for witnesses and any authorities that were contacted.

**42 FINAL HUMAN INTERACTION EVALUATION** – This section should be completed if you circled YES under *Signs of Human Interaction Observed* (#40). It should be completed after filling out the entire data sheet. This section is subjective and takes into account the animal's physical condition, necropsy findings, the timing of the human interaction with respect to the stranding, and the circumstances surrounding the stranding. Most importantly it takes into account the evaluator's level of experience. If you have not conducted many evaluations or are not familiar with the region, you may be unable to make an accurate final evaluation and should circle CBD.

For this section you are estimating how likely you think it is that the documented human interaction contributed to the stranding event. This estimate or confidence interval is expressed in a scale of 0-3, as described below. Circle the most appropriate number. The higher the number, the more likely it is that the interaction contributed to the stranding. If you do not feel that you can provide an evaluation, circle 0 – Uncertain (CBD). [Note: we do not say that the human activity *caused* the stranding because the human interaction could have indirectly contributed to the event without being the direct cause of the stranding.]

0. Uncertain (CBD) – You cannot provide an evaluation of the likelihood that human interaction contributed to the stranding (e.g. a Code 4 carcass is found with propeller marks; it is too decomposed to determine whether the interaction was pre- or post-mortem).
1. Improbable - It is unlikely that the observed human interaction contributed to the stranding (e.g. there are healed entanglement scars on the flukes of a known humpback whale that died with a full-term fetus; it is unlikely that the past entanglement contributed to the stranding).
2. Suspect – It is possible that human interaction contributed to the stranding (e.g. there is a small amount of plastic found in the animal's stomach, but you are unsure of its effect).
3. Probable - It is very likely that human interaction contributed to the stranding (e.g. clear evidence of mutilation, a full stomach, plus one mark that may be indicative of entanglement ).

**43 JUSTIFICATION** – Provide a brief justification of your answer for the *Final Human Interaction Evaluation* score. Include information from all sources available to you.

Please send comments and suggestions regarding these materials to:

[kt2e@capecodstranding.net](mailto:kt2e@capecodstranding.net) or [sgbarco@virginiaaquarium.com](mailto:sgbarco@virginiaaquarium.com)